


9th KPro Study Group meeting, April 12, 2014, Salzburg, Austria



9th KPro Study Group meeting, April 12, 2014, Salzburg, Austria



Claes Dohlman

Joaquin Barraquer

James Aquavella

9th KPro Study Group meeting, April 12, 2014, Salzburg, Austria

9th KPro Meeting

Current KPro's
Indications, Complications and Solutions.
Where are we going?

Christopher
Liu

Angela
Busuttill

Venkata
Avadhanam

Chris
Hull

Kathryn
Colby

Masahiko
Fukuda

Richard
Lee

Konrad
Hille

David
Goldblum

Gerd
Geerling



Günther Grabner

Claes Dohlman

Joaquín Barraquer

James Aquavella

James Chodosh

9th KPro Study Group meeting, April 12, 2014, Salzburg, Austria

9th KPro Meeting

Current KPro's
Indications, Complications and Solutions.
Where are we going?

Dariusz
Dobrowolski

Andrey
Golovin

Yuriy
Kalinnikov

Stanislav
Iakymenko

Petro
Kostenko

Khalid
Al Arfaj

Maria
De La Paz

Cesare
Forlini



Claes Dohlman

Joaquin Barraquer

James Aquavella

James Chodosh

9th KPro Meeting President
Konrad Hille

2014 Meeting Chair and Host
Günther Grabner

Honorary President
Michael Roper-Hall

Honorary Members
Emmanuel Lacombe (1990)
Joaquin Barraquer, Spain (1992)
Giancarlo Falcinelli, Italy (1992)
Claes Dohlman, USA (2003)

Secretary General
Jean-Marie Parel

Associate Secretary General
Deborah Sweeney and Michael Belin

Assistant Secretary General
Mariela C. Aguilar & Alex Gonzalez

2014 Local Organizing Committee
Josef Ruckhofer, Josef Stoiber, Orang Seyeddain

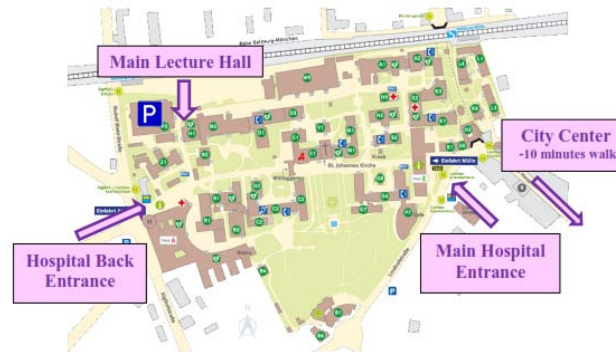
2014 Local Secretarial Organizing Team
Sigrid Sollbauer and Team

2014 Steering Committee*
Jean-Marie Parel, USA (1990)
Eduardo Alfonso, USA (1990)
Bernard Duchesne, Belgium (1999)
Günther Grabner, Austria (2001)
Deborah Sweeney, Australia (2001)
Michael Belin, USA (2008)
Masahiko Fukuda, Japan (2008)
Konrad Hille, Germany (2008)
Donald Tan, Singapore (2008)
James Chodosh, USA (2010)
Christopher Liu, UK (2010)
Srinivas Rao, India (2010)
Jose DeLa Cruz, USA (2012)
Virender Sangwan, India (2012)
Victor Perez, USA (2012)
* Current members (starting date)

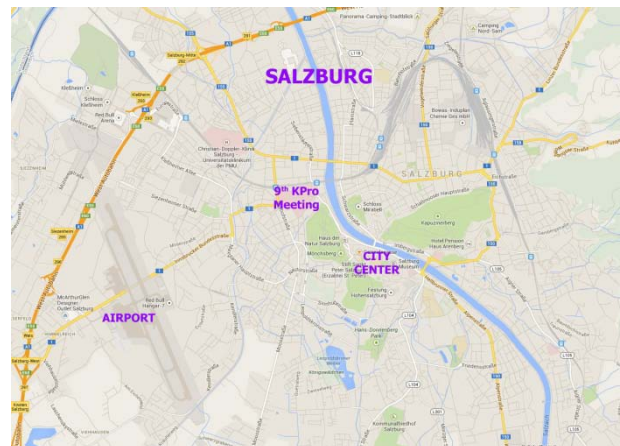
The Local Organizing Committee wishes to cordially thank
Abbott Medical Optics Austria
(Thomas Müllner, Manager, Commercial Business Alpin)
for the generous support of the 9th KPro Meeting.

VENUE

The **Main Lecture Hall**
of the
Landeskliniken Salzburg, Universitätsklinikum
of the **Paracelsus Medical University**
Müllner Hauptstrasse 48, 5020 Salzburg, Austria



For information during the meeting call
+43 662 4482 - 57372 (Dr. Seyeddain)



KPro Study Group

9th KPro Meeting

Current KPro's
Indications, Complications and Solutions.
Where are we going?

April 12, 2014

University Eye Clinic
Paracelsus Medical University
Salzburg, Austria



The 9th KPro Meeting is approved for 10 points of CME (DFP)
by the Austrian Medical Association (ÖÄK).

PARACELSUS
MEDIZINISCHE PRIVATUNIVERSITÄT
Universitätsaugenklinik
Salzburg

Fuchs Stiftung
zur Förderung der Augenheilkunde

9th KPro Meeting

April 12, 2014
Salzburg, Austria



Time	Nr.	Speaker	Topic
08:15		Grabner	Welcome
08:20		Parel	Introduction KPro Study Group
08:25		Stoiber	Meeting Rules
		OOKP	Chair: Aquavella, Liu
08:30	1	De la Paz	Anatomical and functional outcomes of Osteokeratoprosthesis using Tibial Bone
08:40	2	Michael	Long-term-functional and anatomical results of osteo- and osteodontokeratoprosthesis
08:50	3	Hille	Medium and long-term results in keratoprostheses with biological support
09:00	4	Fukuda	Modified Osteo-Odonto-Keratoprostheses in Japan
09:10	5	Staab	Cost of Osteo-Odonto-Keratoprostheses and Tibia-Keratoprostheses-in Germany
09:20	6	Amescua	Modified Osteo-Odonto Keratoprosthesis: The Miami Experience
09:30	7	Lee	Visual functional performance of OOKP optical cylinders
09:38	8	Hull	Optical analysis of the UK Osteo-Odonto-keratoprosthesis optical cylinder
09:46	9	Busutil	Measuring Quality of Life after OOKP Surgery
09:50	10	Barraquer	Keynote Lecture: The evolution of keratoprosthesis 1955-2014
10:10		Discussion	
10:30-11:00		Poster Oral Presentation 1	Chair: Duncker, Duchesne
	P1	Salvador-Culla	Titanium to enhance biointegration of the Boston Keratoprosthesis with corneal tissue: a study in rabbits
	P2	Salvador-Culla	Very low Risk of Light-induced Retinal Damage during Boston Keratoprosthesis Surgery
	P3	Robert	Tear Matrix Metalloproteinases and Myeloperoxidase Levels Following Boston Keratoprosthesis Type I surgery
	P4	Crnei	Glaucoma Progression and Role of Glaucoma surgery in Patients with Boston Keratoprosthesis
	P5	Crnei	A novel murine model for keratoprosthesis research
	P6	Kobuch	The MIRO KPro - a new designed one-material implant with modified surfaces.
	P7	White	Incidence of Stevens-Johnson Syndrome and Chemical Burns to the Eye. Relevance for KPro Surgery
11:00-11:30		Coffee Break	Discussion at the posters with coffee
		BOSTON Part 1	Chair: Barraquer, Parel
11:30	11	Teichman	Type 1 Boston Keratoprosthesis: The Ontario Experience
11:40	12	Al Arfai	Complications and Retention Rate of Threadless Type I Boston Keratoprosthesis in eastern Province of Saudi Arabia
11:50	13	Wylegala	Polish Experience with Boston Type I Keratoprosthesis
12:00	14	Seyeddain	Results of Boston Type I KPro in Salzburg and Barcelona
12:10	15	Gu Jianjun	Boston type 1 keratoprosthesis outcomes and complications: results from the Zhongshan Ophthalmic Center
12:20	16	Chodosh	Boston Keratoprosthesis in autoimmune disorders
12:30	17	Aquavella	Keynote Lecture: The infant KPro: team, logistics and results with surgical techniques and postoperative management
12:50		Discussion	
13:00-14:00		Lunch Break	
		Other and New KPro's	Chair: Dohlman, De La Paz
14:00	18	Moroz	Russian KPro's: types, technique and results
14:10	19	Duncker	The fully synthetic MIRO keratoprosthesis - report on development, animal experiments, and first clinical results
14:20	20	Wand	Biosynthetic corneal collagen implants - reports on ex vivo, in vivo and clinical experiences - EU-Nanomed I-care Project
14:30	21	Duchesne	My Belgian experience in Keratoprosthesis
14:40	22	Charonis	A new type of temporary keratoprosthesis in the drawing board - 2 Minutes VIDEO
		New Clinical and Experimental	Chair: Moroz, Stoiber
15:00	23	Tan	Effectiveness of immobilized antimicrobial peptide for preventing perioperative corneal implant associated infection
15:10	24	Durkee	Relationship between surface features and biofilm formation of explanted KPros imaged with confocal microscopy
15:20	25	Menabuoni	One touch femtosecond laser KPro
15:30	26	Paschalis	In Vitro and in Vivo Assessment of Titanium Surface Modification for Coloring the Back Plate of the Boston Keratoprosthesis
15:40	27	Amescua	Use of Intraocular Video Endoscopic Examination in the Preop. Evaluation of KPro.
15:50		Discussion	
16:00-16:30		Poster Oral Presentation 2	Chair: Wylegala, Forlini
	P8	Paschalis	Alkali Burn to the Eye: Protection using TNF- α inhibition
	P9	Paschalis	A Novel Implantable Glaucoma Valve Using Ferrofluid
	P10	Taniguchi	The role of Tumor Necrosis Factor Alpha in Glaucoma after Boston Keratoprosthesis: Preliminary Data
	P11	Sippel	Surface Epithelialization of the Type I Boston Keratoprosthesis Front Plate: Immunohistochemical and High-Definition Optical Coherence Tomography Characterization
	P12	Teichman	Evaluation of trephine adapter for preparation of corneal tissue during Boston KPro Surgery
	P13	Cruzat	Oversized titanium back plate in Boston Keratoprosthesis: anatomical results
	P14	Fukuda	A case of Ahmed glaucoma valve implantation for secondary glaucoma after MOOKP
	P15	Robert	Long-term outcomes of frozen and fresh corneal donor carriers for keratoprosthesis surgery
	P16	Ciolino	A drug eluting contact lens
16:30-17:00		Coffee Break	Discussion at the posters with coffee
		Complications and Management	Chair: Hille, Chodosh
17:00	28	Forlini M	Endoscopic Cyclophotocoagulation in Refractory Glaucoma after Osteo-Odonto-Keratoprosthesis in Stevens-Johnson Syndrome
17:10	29	Wang	Management of Corneal Melt Associated with Keratoprosthesis
17:20	30	Neuhann	Reusing a Boston KPro in the management of corneal melting: Report of three cases
17:30	31	Utine	Management of recurrent retroprosthetic membrane formation following Boston type 1 keratoprosthesis implantation
17:40	32	Grassi	Sterile Vitritis after Boston Keratoprosthesis
17:50	33	Rooney	Retinal detachment prevention in K-Pro eyes
18:00	34	Forlini C	Management of retinal detachment in osteo-odonto keratoprosthesis (OOKP): Case report
18:10	35	Jain	Retinal Detachments in Eyes After Boston Keratoprosthesis Type 1
18:20	36	Miller	Treatment Outcomes Cystoid Macular Edema in Patients with Boston Type 1 Keratoprosthesis
18:30		Discussion	
		BOSTON Part 2	Chair: Aquavella, Grabner
18:50	37	Akpek	Donor Corneal Transplantation versus Boston Type I Keratoprosthesis in Patients with Previous Graft failures: A Retrospective Single Center Study
19:00	38	Etzebarria	Modification of Boston KPro type I surgery for cases with previous KPro extrusion
19:10	39	Colby	Wound anatomy following Boston KPro
19:20	40	Rudnisky	Boston Keratoprosthesis multicenter study: retention and vision.
19:30	41	Chodosh	Globalization of keratoprosthesis surgery
19:40	42	Dohlman	Keynote Lecture: Remaining obstacles for artificial corneas ?
19:50		Discussion	
20:00		Closing of Session	Short walk to restaurant



KPro Study Group

9th KPro Meeting

**Current KPro's
Indications, Complications and Solutions.
Where are we going?**

April 12, 2014

**University Eye Clinic
Paracelsus Medical University
Salzburg, Austria**



**Universitätsaugenklinik
Salzburg**

**Fuchs Stiftung
zur Förderung der Augenheilkunde**





KPro Study Group

9th KPro Meeting
April 12, 2014 Salzburg, Austria



9th KPro Meeting President
Konrad Hille

2014 Meeting Chair and Host
Günther Grabner

Honorary President
Michael Roper-Hall

Honorary Members
Emmanuel Lacombe (1990)
Joaquin Barraquer, Spain (1992)
Giancarlo Falcinelli, Italy (1992)
Claes Dohlman, USA (2003)

Secretary General
Jean-Marie Parel

Associate Secretary General
Deborah Sweeney and Michael Belin

Assistant Secretary General
Mariela C. Aguilar & Alex Gonzalez

2014 Local Organizing Committee
Josef Ruckhofer, Josef Stoiber, Orang Seyeddain

2014 Local Secretarial Organizing Team
Sigrid Sollbauer and Team

2014 Steering Committee*
Jean-Marie Parel, USA (1990)
Eduardo Alfonso, USA (1990)
Bernard Duchesne, Belgium (1999)
Günther Grabner, Austria (2001)
Deborah Sweeney, Australia (2001)
Michael Belin, USA (2008)
Masahiko Fukuda, Japan (2008)
Konrad Hille, Germany (2008)
Donald Tan, Singapore (2008)
James Chodosh, USA (2010)
Christopher Liu, UK (2010)
Srinivas Rao, India (2010)
Jose DeLa Cruz, USA (2012)
Virender Sangwan, India (2012)
Victor Perez, USA (2012)

** Current members (starting date)*

The Local Organizing Committee wishes to cordially thank
Abbott Medical Optics Austria (Thomas Müllner, Manager, Comm. Business Alpin)
for the generous support of the 9th KPro Meeting.



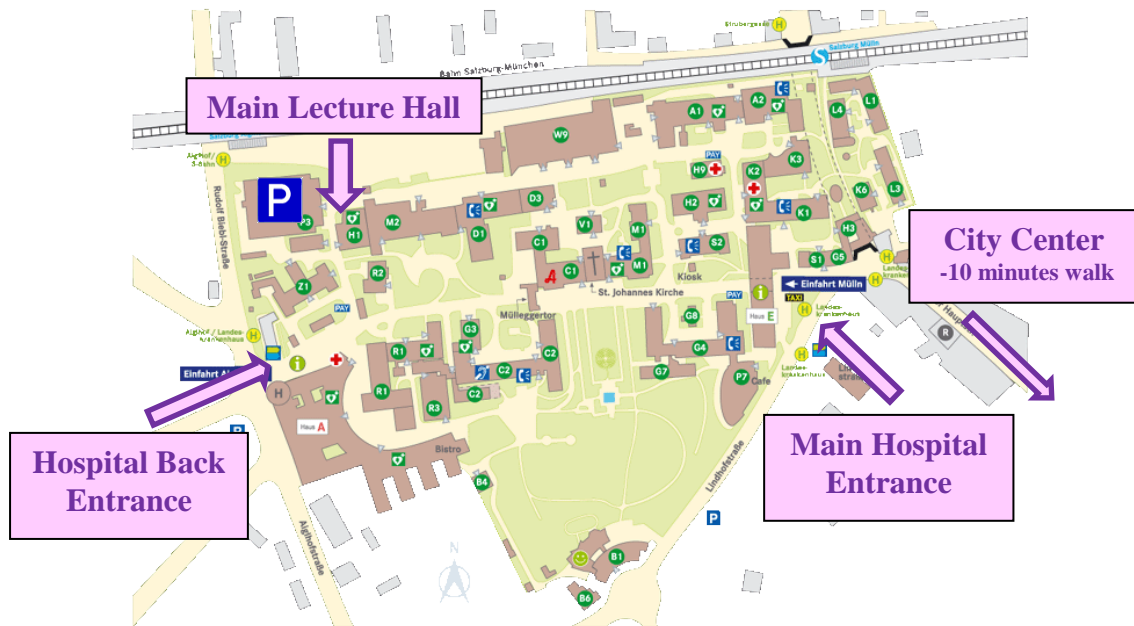
KPro Study Group

9th KPro Meeting
April 12, 2014 Salzburg, Austria

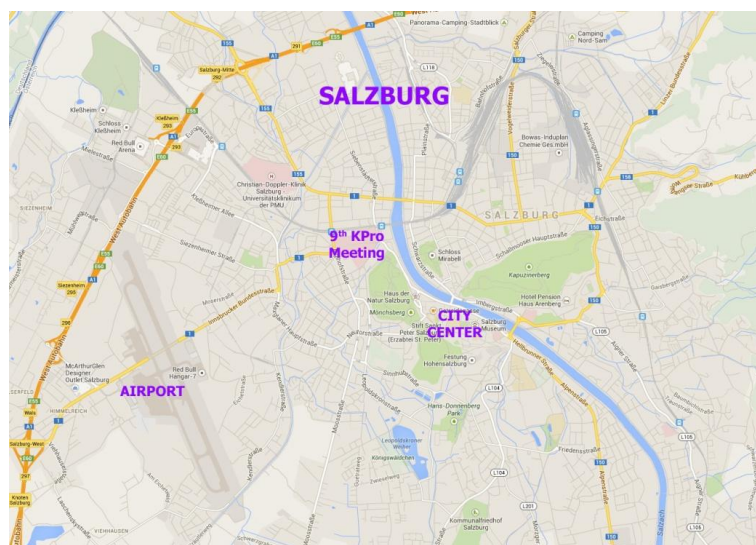

VENUE

The **Main Lecture Hall**
of the
Landeskliniken Salzburg, Universitätsklinikum of the Paracelsus Medical University
Müllner Hauptstrasse 48, 5020 Salzburg, Austria



For information during the meeting call +43 662 4482 - 57372 (Dr. Seyeddain)



The 9th KPro Meeting is approved for 10 points of CME (DFP) by the Austrian Medical Association (ÖÄK).



OSTEO-ODONTO KERATOPROSTHESIS

Chair: J. Aquavella, C. Liu

1

Title: Anatomical and functional outcomes of Osteokeratoprosthesis using Tibial bone

Authors: Maria Fideliz de la Paz, Victor Charoenrook, Angela Ding, Jose Temprano, Rafael I. Barraquer, Ralph Michael

Affiliation: Centro de Oftalmología Barraquer, Barcelona, Spain

Objective: To analyse and report the anatomical and the functional results of keratoprosthesis using tibial bone autograft; to analyse the influence of factors such as primary diagnosis, age and postoperative complications, on the final outcomes.

Method: We reviewed 113 charts of patients that underwent Tibial Osteokeratoprosthesis (Tibial bone Kpro) surgery at the Centro de Oftalmología Barraquer, Barcelona, between the years 1987 and 2013. Those patients that were operated on both eyes, we selected randomly only one for the study to avoid the bias of its bilaterality. The mean follow up time was 4 years. Kaplan-Meier survival curves were calculated for functional success, defined as BCVA \geq 0.05 on decimal scale and anatomical success, defined as retention of the keratoprosthesis lamina.

Results: Based on Kaplan-Meier analyses, 5-year and 10-year anatomical survival rate was 70% and 54% respectively. For functional survival, 5-year rate was 34% and 10-year rate was 19%. Considering the primary diagnosis, chemical and thermal burn had the highest anatomical survival rate at 10 years. Chemical burn, OCP and Steven Johnson syndrome had the best functional survival rate. Patients with age between 70-89 years have better survival rates both for anatomical and functional outcomes than other age groups. About 40% of the patients had complications, with glaucoma and retinal detachment the most common ones.

Conclusion: Half of the patients with Tibial bone Kpro still have the keratoprosthesis after 10 years of surgery and one-fifth of them still have a vision of \geq 0.05 at the same period. Considering that these patients have no other way to recover their vision either because they have no canine tooth or their buccal or dental conditions are not adequate for OOKP, this modified surgery is their only hope.

Study supported by: N/A

Conflict of interest: None

Corresponding author email address: ralph.michael@gmx.net



Title: Long-term functional and anatomical results of osteo- and osteodonto-keratoprosthesis

Authors: Ralph Michael, Miriam J. Allende, Maria Fideliz de la Paz, Victor Charoenrook, Jose Temprano, Rafael I. Barraquer

Affiliation: Centro de Oftalmología Barraquer, Barcelona, Spain

Objective: To analyze the 20 year anatomical and functional survival, evaluating primary diagnosis, age and post-surgical complications.

Methods: We reviewed 145 charts of patients that underwent osteodonto-keratoprosthesis (OOKP) at the Centro de Oftalmología Barraquer, between 1974 and 2005. Kaplan-Meier survival curves were calculated for functional success defined as BCVA > 0.05. Anatomical success was defined as retention of the keratoprosthesis lamina. Primary diagnosis included chemical burn (n=63), thermal burn (n=14), Steven Johnson syndrome or Lyell syndrome (n=21), ocular cicatricial pemphigoid (n=8), trachoma (n=24) and other or not assignable (n=15). Mean follow-up time was 9.5 years. Twenty years after implantation, 21 were still anatomically successful, 39 had failed before and 85 were lost to follow-up.

Results: Based on Kaplan-Meier analyses, average 20 year anatomical survival was 60%. Patients with thermal burn or with other or not assignable diagnosis performed better than the average patient (about 90%), chemical burn and Stevens-Johnson or Lyell syndrome performed like the average, trachoma was slightly worse (45%) and no patient with ocular cicatricial pemphigoid reached even 10 years with anatomical success. Age had no effect on anatomical survival. Patients with detected post-operative glaucoma performed better than average, multiple complications or infections lowered the anatomical success rate to 38% or 29% respectively. Average 20 year functional survival was 28%. Patients with Stevens-Johnson or Lyell syndrome performed slightly better than the average patient (42%), chemical burn or other or not assignable diagnosis performed like the average, thermal burn and trachoma had worse results (19% and 10% respectively). Patients between 30 and 69 years performed slightly better (about 33%), younger than 29 years slightly worse (24%). As expected no patient older than 70 years at surgery had functional useful vision 20 years later. Best performance had the group with no complications (48%). Patients with retinal detachment, post-operative glaucoma and multiple complications had worse functional results with 17, 14 and 13% respectively. No patient with infections had functional useful vision 20 years after surgery.

Conclusion: Patients with chemical burn or Stevens-Johnson or Lyell syndrome have the best anatomical and functional results. OCP had the worst anatomical results. Patients with thermal burn (often explosions) had good anatomical but low functional success. Infections and multiple complications lower anatomical and functional success considerably.

Study supported by: N/A

Conflict of interest: None

Corresponding author email address: ralph.michael@gmx.net



KPro Study Group

9th KPro Meeting
April 12, 2014 Salzburg, Austria



3

Title: Medium and long-term results in keratoprostheses with biological support

Authors: Konrad Hille, Kerstin Beck

Affiliation: Augenklinik des Ortenauklinikums Offenburg-Gengenbach, Josefsklinik, Weingartenstraße 70, 77654 Offenburg, Germany.

Objective: To update and demonstrate medium to long-term results in keratoprosthesis with biological support mounted by a dento-alveolar lamina (Osteo-Odonto-Keratoprostheses, OOKP) and a tibia-corticalis lamina (Tibia-Keratoprostheses, TKPro)

Methods: In the last 19 years we implanted 64 KPro (44 OOKP and 20 TKPro). There was a follow up examination about every half a year. We collected the data by reviewing the patient's records (retrospectively) and examining the current state if possible.

Results: The medium follow up was 7 years with a maximum of 17 years and a minimum of 2 months in OOKP and 04/03 years/months (max. 10/01 years/months, min. 5 months) in TKPro. With an OOKP the patients gained a visual acuity of $\geq 0,8$ in 34 %, of $\geq 0,5$ in 55 %, of $\geq 0,2$ in 73 % and a significant improvement of the visual acuity in 84 % and in TKPro 6 %, 35 %, 65 % and 71 % respectively. In OOKP patients there was a deterioration of visual acuity (more than 2 lines) in 6 patients and 1 patient in TKPro. A secondary glaucoma was found in 5 of OOKP (11%) and 3 of TKPro (15%). 3 (7 %) of the OOKP had to be explanted (because of rheumatic melting down of the mucous membrane and the prosthesis in one patient; exposed dentine haptic with fistulation in the other two) and 2 (10%) of the TKPro (resorption of the bone).

Conclusions: In KPro with biological support we can expect a satisfying medium and long term rehabilitation of vision. Complications can be managed in most cases, only in a few they may lead to a loss of the prosthesis.

Study supported by: N/A

Conflict of interest: None

Corresponding author email address: augenheilkunde@og.ortenau-klinikum.de



Title: Modified Osteo-odonto-keratoprosthesis in Japan

Authors: Masahiko Fukuda¹, Keizo Watanabe¹, Koji Sugioka¹, Suguru Hamada², Christopher Liu³, Masakazu Yamada⁴, Shiro Amano⁵, Etsuo Chiraha⁶, Yoshikazu Shimomura¹

Affiliations: ¹Department of Ophthalmology, Kinki University Faculty of Medicine, ²Department of Oral Surgery, Kinki University Faculty of Medicine, ³Sussex Eye Hospital, Brighton, UK, ⁴Kyorin Eye Center, ⁵Department of Ophthalmology, Tokyo University School of Medicine, ⁶Chihara Eye Clinic, Japan.

Objective: Modified Osteo-odonto-keratoprosthesis (MOOKP) is reported to be useful for restoring sight in patients with end stage severe ocular surface diseases such as Stevens-Johnson syndrome (SJS). We reviewed our cases and investigated the efficacy of MOOKP.

Patients: We performed MOOKP to six cases since June 2003. There were Stevens-Johnson syndrome (4 cases), ocular cicatricial pemphigoid (1 case) and bilateral severe chemical burn (1 case). Age range and sex of the cases were between 47 and 71 years, two males and four females. Visual acuities before surgery were all CF or less. The best corrected visual acuities after surgery were 1.2 (2 cases), 0.6 (1 case), 0.1 (1 case) and 0.04 (1 case). The follow up period ranged between 1 year 6 months and 10 years. The complications observed were secondary glaucoma (1 case), tilting of the optical cylinder (1 case), mucosal overgrowth (1 case) and mucosal defect (1 case). We performed the valve-shunt surgery for the glaucoma case.

Conclusion: We confirmed that MOOKP was useful for the treatment of severe end stage ocular surface diseases.

Study supported by: N/A

Conflict of interest: None

Corresponding author email address: fukuda-m@med.kindai.ac.jp



- Title:** Expense of Osteo-Odonto-Keratoprotheses and Tibia-Keratoprotheses-in Germany
- Authors:** Iris Staab¹, Gerd Geerling¹, Konrad Hille²
- Affiliations:** ¹Augenklinik Universität Düsseldorf, ²Augenklinik des Ortenauklinikums Offenburg-Gengenbach, Josefsklinik, Weingartenstraße 70, 77654 Offenburg, Germany.
- Objective:** To evaluate the costs of Osteo-Odonto-Keratoprosthesis (OOKP) or Tibia-Keratoprosthesis (TKPro) surgery in Germany
- Methods:** Retrospective chart review of 32 OOKP or TKPro implantations by Hille from 1996 to 2005. Costs of hospital accommodation, pre and postoperative medical care, surgery including materials and personel of routine KPro surgery and management of complications.
- Results:** The costs for preparing an OOKP add up to € 9.015 for preparation and € 7.896 for implantation of an OOKP or TKPro.
- Conclusions:** Although the economic costs of blindness are higher than the real expense of keratoprosthesis surgery, these costs are not specifically reflected in the German DRG-system.
- Study supported by: N/A
- Conflict of interest: None
- Corresponding author email address: g.geerling@med.uni-duesseldorf.de



- Title:** **Modified Osteo-Odonto Keratoprosthesis: The Miami Experience**
- Authors:** Guillermo Amescua¹, Charles C. Farias^{1,2}, Victor L. Perez¹, Hilal Ozturk¹; Yoh Sawatari¹, Giancarlo Falcinelli¹, Jean-Marie Parel^{1,2}
- Affiliations:** ¹Department of Ophthalmology and ²Ophthalmic Biophysics Center, Bascom Palmer Eye Institute, University of Miami/Miller School of Medicine; Miami, FL, USA.
- Objective:** To report the long-term functional and anatomic outcome of MOOKP surgery in the visual rehabilitation of patients with end-stage ocular surface disorders.
- Methods:** Retrospective, noncomparative and interventional study of four consecutive cases that underwent a MOOKP procedure following the standard 3-stages described by Facinelli. The preoperative diagnosis of these patients were SJS (n=3) and bilateral alkali chemical injury (n=1). Three patients had a history of multiple failed corneal surgeries or ocular surface transplantation procedures and were judged poor risks for standard keratoplasty. The better or only eye had poor vision, such as light perception (LP) or hand motion (HM). Major outcomes were KPro anatomical retention, visual acuity, and complications.
- Results:** MOOKP surgical procedure was performed in a total of 4 eyes of 4 patients. One patient was female and three were male. Age ranged from 40 to 65 years (median, 55.7). Three patients had preexisting glaucoma and 2 had undergone a glaucoma valve implant and one was controlled medically; one had had 6 previous penetrating keratoplasty (PK), 3 patients had preceding operations including superficial keratectomy, extracapsular cataract extraction, autologous limbal transplantation, amniotic membrane transplantation, autologous salivary gland transplantation, keratolimbal allograft (KLAG) and tarsorrhaphy. The mean follow up was 18.5 months. Anatomical retention of the KPro has been maintained in two eyes. Functional success of visual acuity $\geq 20/25$ was archived in 2 patients for at least 11 months of follow-up. Complication included mucosal defects, infection, cylinder displacement, endophthalmitis and bone reabsorption.
- Conclusions:** MOOKP remains the best treatment option for patients with severe end-stage ocular surface damage and corneal blindness. Vision recovery is directly related to the stability of the prosthesis. This is not a procedure without complications that once detected must be quickly addressed.
- Study supported by:** USAMRMC Department of Defense Grant#W81XWH-09-1-0675, NIH Center Core Grant P30EY014801; Unrestricted grant from Research to Prevent Blindness
- Conflict of interest:** None
- Corresponding author email address:** gamescua@med.miami.edu



Title: Visual functional performance of OOKP optical cylinders

Authors: Richard M H Lee¹, Gek L Ong¹, Fook Chang Lam¹, Joy White¹, David Crook², Christopher S C Liu^{1,3}, Chris C Hull⁴

Affiliations: ¹Sussex Eye Hospital, Brighton, United Kingdom, ²Royal Sussex County Hospital, Brighton, United Kingdom, ³Tongdean Eye Clinic, Hove, United Kingdom, ⁴City University London, London, United Kingdom

Objective: To evaluate the visual functional performance of the osteo-odonto keratoprosthesis (OOKP).

Methods: Nine patients with implanted OOKP devices and nine age-matched control patients were assessed. Contrast sensitivity was assessed and glare effect was measured with a brightness acuity test (BAT). All OOKP patients underwent kinetic Goldmann perimetry, wavefront aberrometry and completed the National Eye Institute Visual Function Questionnaire-25 (NEI VFQ-25).

Results: A reduction in mean visual acuity (logMAR) with increasing glare settings was observed from 0.12 without glare to 0.27 with glare (BAT at 'High' setting) and significantly reduced statistically when compared to the control group under medium ($P = 0.02$) and high ($P = 0.01$) levels of glare. Contrast sensitivity was significantly reduced when compared to age-matched controls at medium and high spatial frequencies. Mean Goldmann perimetry was 62° (range 24 to 88°, V-4e isopters) and 71° excluding two glaucomatous subjects. Several vision-related VFQ-25 sub-scales correlated significantly with visual acuity at various BAT levels and contrast sensitivity at medium spatial frequencies, including General Vision, Near and Distance Activities.

Conclusions: The OOKP optical cylinder provides patients with a good level of visual acuity that is significantly reduced by glare.

Study supported by: N/A

Conflict of interest: None

Corresponding author email address: rmhleuk@gmail.com



Title: Optical analysis of the UK Osteo-odonto-keratoprosthesis optical cylinder

Authors: Chris C Hull¹, Samantha Gode¹, Richard M H Lee², Gek L Ong², Fook Chang Lam², Joy White², David Crook³, Christopher S C Liu^{2,4}.

Affiliations: ¹City University London, London, United Kingdom, ²Sussex Eye Hospital, Brighton, United Kingdom, ³Royal Sussex County Hospital, Brighton, United Kingdom, ⁴Tongdean Eye Clinic, Hove, United Kingdom

Objective: To evaluate the optical properties of the UK designed OOKP optical cylinder with specific emphasis on forward light scatter.

Methods: Finite ray tracing analysis was used (Zemax EE, version 2010) to evaluate the field of view and axial image quality having first moved the image plane (retina) to optimize the modulation transfer function at 30cpd (equivalent to optimum refraction for a visual acuity of 20/20). Optical cylinders were then tested for forward light scatter using a diffuse point source from a laser at eccentricities out to 17 degrees by recording the light falling on an axially located detector. During testing, cylinders were surrounded by white PTFE (a surrogate for the osteo-odonto lamina) and the cylinder walls were treated by polishing, frosting, blackening or a combination of these treatments. In addition, a light oil ($n=1.453$) was used between the cylinder walls and the osteo-odonto lamina surrogate to see if material surrounding the cylinder altered forward light scatter. Results were analysed qualitatively and by calculating the light detected under the light scatter function for eccentricities >1.25 degrees. Quantitative data were statistically analysed with a one-way ANOVA and post hoc comparison of means using Fisher's least significant difference test.

Results: Ray tracing analysis demonstrated that the optical cylinder is near diffraction-limited with a root-mean square wavefront error of 0.04microns. This equates to the total spherical aberration under the assumptions of the analysis. Theoretical field of view is limited to 72 degrees. However the analysis revealed a rapid fall in image quality and vignetting that will reduce the retinal illuminance potentially affecting visual field results. Forward light scatter of the current cylinder design with polished walls was 1.58x higher than a PMMA IOL used as a comparison. Blackening the cylinder walls did not significantly affect the light scatter ($P>0.05$ all cases) whereas frosting the walls significantly increased the forward light scatter ($P<0.05$ all cases). Changing the refractive index at the cylinder wall with a light oil increased forward light scatter if the cylinder wall was frosted. For polished wall cylinders there was no statistically significant change ($P>0.05$).

Conclusions: Improvements in field of view require changes to the cylinder geometry (length and posterior section diameter). Treatments to the walls of the cylinder in general increased forward light scatter although specular reflections from the polished walls remain to be investigated further. Disability glare suffered by patients could be caused by the lack of a mobile pupil at higher light levels. The influence of the refractive index at the walls of the cylinder has implications for any material between the cylinder and osteo-odonto lamina.

Study supported by: We are grateful to Morcher GmbH who provided the optical cylinders used in this study.

Conflict of interest: None

Corresponding author email address: c.c.hull@city.ac.uk



- Title:** **Quality of Life after OOKP Surgery**
- Authors:** Busuttil A., Southall D., Avadhanam V., Liu CSC.
- Affiliation:** Sussex Eye Hospital Brighton, United Kingdom
- Objective:** Assessment of quality of life (QoL), is important in evaluating the overall benefits of OOKP surgery. QoL includes physical, psychological, social and economic variables and factors such as treatment burden also need consideration. The adaptation of the Visual Function Questionnaire-25ⁱ for use with OOKP patients will be described together with its use in a study to measure health related quality of life in 20 patients at 12 months post OOKP surgery. Correlation of QoL measures with visual acuity will be discussed.
- Methods:** Previous qualitative research undertaken with OOKP patients informed questionnaire item selection of the OOKP adapted VFQ-25. Face to face and telephone interviews were then conducted with patients using the OOKP adapted VFQ-25.
- Results:** The OOKP adapted VFQ-25 had high patient acceptability. It proved a useful global measure to evaluate health related quality of life post OOKP surgery with 80% of patients reporting significant improvements in quality of life.
- Conclusions:** Visual acuity was moderately positively correlated with QoL outcomes. Variables other than visual acuity need to be considered when evaluating the benefits of OOKP surgery. An OOKP vision related quality of life measure can contribute to the evaluation of outcome and provide useful feedback to those commissioning services.
- Study supported by:** NHS England commissioned service.
- Conflict of interest:** None
- Corresponding author email address:** angela.busuttil@sussexpartnership.nhs.uk

VFQ-25 freely available for use in research with following acknowledgements: developed by RAND supported by National Eye institute. Mangione CM, Lee PP, Gutierrez PR, et al. Development of the 25-item National Eye Institute Visual Function Questionnaire (VFQ-25). Arch Ophthalmol. 2001 Jul;119(7):1050-8



10

KEYNOTE LECTURE:

THE EVOLUTION OF KERATOPROSTHESIS 1955 - 2014

- Authors:** Prof. Joaquin Barraquer, María de la Paz, Juan Alvarez de Toledo
- Affiliation:** Centro de Oftalmología Barraquer and Institut Universitari Barraquer, Barcelona, Spain
- Objective:** To describe the Barcelona experience with the different types of keratoprostheses for desperate cases of cicatricial corneal disease.
- Methods:** 6 cases are presented, illustrating various types of keratoprostheses which we have used at the Barraquer Eye Center from 1955 to present.
- Results:** We describe the first keratoprosthesis ever implanted in Spain, in a case of severe chemical burn on both eyes of a young lady in 1955. We implanted a Dorzee acrylic keratoprosthesis. The patient sustained a good functional and anatomical result until 5 years later when she had extrusion of the prosthesis and superior retinal detachment. The second case demonstrates the characteristics of the Dorzee-Barraquer-Cardona acrylic keratoprosthesis implanted in 1958 on a patient with end-stage glaucoma. The patient had good anatomical retention until his death in 1970. The third case shows chronic graft failure after 2 corneal transplants. A Cardona keratoprosthesis was implanted in 1960. The patient had a good anatomical and functional result for 8 years until acute endophthalmitis developed. The fourth case demonstrates the expulsion of a Teflon-supported keratoprosthesis designed by Girard. The fifth case illustrates the first implantation of an osteo-odontokeratoprosthesis designed by Strampelli in a case of blast injury showing good anatomical and functional results for 10 years. The last case refers to our experience with the Boston keratoprosthesis which we started using in 2006.
- Conclusions:** Our clinical experience for more than 50 years with the implantation of keratoprostheses at the Barraquer Eye Center shows that the acrylic keratoprosthesis of Dorzee implanted for the first time in the 1950's has slowly evolved to the present day widely used Boston keratoprosthesis. While the surgical technique, design and post-operative treatment of both biological and non-biological keratoprostheses have improved over the years, the anatomical and functional results continue being a challenge for the KPro surgeon considering the relatively high frequency of unexpected, unresolvable, sight-threatening complications.
- Study supported by:** N/A
- Conflict of interest:** None
- Corresponding author email address:** mpaz@barraquer.com



POSTER ORAL PRESENTATION (PART 1)

3 slides and 3 minutes each with 1 Question

Chair: G. Duncker, B. Duchesne

P1

Title: Titanium to enhance biointegration of the Boston Keratoprosthesis with corneal tissue: a study in rabbits

Authors: Borja Salvador-Culla^{1,3,4}; Kyung Jae Jeong²; Homer H. Chiang³; James Chodosh¹; Claes H. Dohlman¹; Daniel S. Kohane^{3,4}

Affiliations: ¹Massachusetts Eye & Ear Infirmary, Harvard Medical School, Boston, MA; ²Department of Chemical Engineering, University of New Hampshire, Durham, NH; ³Kohane Laboratory for Biomaterials and Drug Delivery, Harvard Medical School, Boston, MA; ⁴Langer Laboratory, Koch Institute, Massachusetts Institute of Technology, Cambridge, MA, USA

Objective: To test the feasibility of using titanium (Ti) and titanium oxide coatings to improve the biointegration of Boston Keratoprosthesis (B-KPro), and ultimately decrease the risk of various implant-associated complications, such as endophthalmitis.

Methods: Cylindrical rods of poly(methyl methacrylate) (PMMA) (15 mm in length, 3.5 mm in diameter) were coated with titanium dioxide (TiO₂) over a layer of polydopamine. Medical grade titanium rods with two different surface roughnesses (smooth and sandblasted) were also prepared. Some of the Ti rods were treated by oxygen plasma for 5 min in order to increase the surface titanium oxide layer. The surface of each rod was imaged by scanning electron microscopy (SEM), and its surface roughness was estimated by atomic force microscopy (AFM). Surface chemistry was analyzed by X-ray photoelectron spectroscopy (XPS). The rods were fitted into holes punched into the center of porcine corneas ex vivo (1 cm in diameter) and the whole constructs were cultured in modified Chen's media. The adhesion force between the rod and the cornea was measured at days 0 and 14 of incubation to assess the degree of biointegration. In vitro viability of corneal fibroblasts on each surface was measured using alamarBlue. The material with the best adhesion ex vivo was used for in vivo implantation in rabbits. Therefore, a Ti_{ox} sleeve was placed around the stem of the B-KPro, and tissue response was assessed after 2 months.

Results: XPS and AFM showed successful deposition of TiO₂ on polydopamine-coated PMMA, with a resulting increase in surface roughness. Cell viability was not affected adversely by any of the samples. After 14 days of incubation in porcine corneas, TiO₂-coated PMMA rods and smooth titanium rods treated with oxygen plasma (Ti_{ox}) had significantly higher adhesion forces (0.331N and 0.357N) compared to bare PMMA (0.0947N) and untreated Ti rods (0.132N). Tissue reaction around the Ti_{ox} sleeve around the stem after 2 months was benign.

Conclusions: TiO₂-polydopamine coating of PMMA and Ti_{ox} showed a significant increase in adherence to corneal tissue ex vivo. Because Ti_{ox} showed higher values than TiO₂, it was used in vivo as a sleeve around the stem of the B-KPro, and showed benign tissue reaction after 2 months. Therefore, Ti_{ox} may be the preferable choice in patients.

Study supported by: Boston KPro Funds, Massachusetts Eye and Ear Infirmary, Boston, MA, USA

Conflict of interest: None

Corresponding author email address: borja_salvador@meei.harvard.edu salvaculla@hotmail.com



KPro Study Group

9th KPro Meeting
April 12, 2014 Salzburg, Austria



P2

Title: Very low Risk of Light-induced Retinal Damage during Boston Keratoprosthesis Surgery

Authors: Borja Salvador-Culla¹; Irmgard Behlau¹; Rony R. Sayegh¹; Rebecca C. Stacy²; Claes H. Dohlman¹; François Delori³

Affiliations: ¹Cornea Service, Massachusetts Eye & Ear Infirmary, Harvard Medical School, Boston, MA, USA; ²Ophthalmic Pathology, Massachusetts Eye & Ear Infirmary, Harvard Medical School, Boston, MA, USA; ³Schepens Eye Research Institute, Harvard Medical School, Boston, MA, USA

Objective: To assess the possibility of light damage to the retina by a surgical microscope during implantation of a Boston Keratoprosthesis (B-KPro) in rabbits.

Methods: The retinal irradiance from a Zeiss OPMI Lumera S7 operating microscope was measured at the working distance (16.5 cm). Light transmittance through an isolated B-KPro was measured. A B-KPro was implanted into one eye of 12 rabbits with the optic of the device initially covered during the procedure. Retinoscopy was performed after implantation, and external additional lenses were used when needed to focus the light on the retina. The operated eyes were then continuously exposed to a fixed light intensity under the microscope for 1 hour. Fluorescein angiography (FA) was carried out at days 2 and 9 post-surgery, after which the animals were euthanized and the eyes enucleated. Furthermore, we compared the potential of these retinal exposures to well accepted light safety guidelines applicable to humans.

Results: Light transmittance of B-KPro revealed blockage of short wavelengths (<390nm) and of long wavelengths (1660-1750nm) of light. In addition, the surgical microscope filtered part of the blue, ultraviolet (UV), and infrared (IR) wavelengths. Neither FA nor histological examination showed any morphological retinal changes in our rabbits. Moreover, the retinal exposures were well below the safety limits.

Conclusions: Modern surgical microscopes incorporate filters that block the most damaging wavelengths of light. The B-KPro is made of 100% PMMA, which makes it in itself a blocker of short wavelengths of light. No damage could be demonstrated in the animal study, and the retinal exposures were well below the safety limits. Together, these results suggest that light exposures during B-KPro surgery present a low risk of photochemical damage to the retina.

Study supported by: Boston KPro Funds, Massachusetts Eye and Ear Infirmary, Boston, MA, USA

Conflict of interest: None

Corresponding author email address: borja_salvador@meei.harvard.edu salvaculla@hotmail.com



Title: Tear Matrix Metalloproteinases and Myeloperoxidase Levels Following Boston Keratoprosthesis Type I surgery.

Authors: Marie-Claude Robert^{1,2}, Samer Arafat^{1,2}, Sandra Spurr-Michaud², James Chodosh¹, Claes H Dohlman¹, Ilene K Gipson²

Affiliations: ¹Massachusetts Eye and Ear Infirmary, 243 Charles St; ²Schepens Eye Research Institute, 40 Staniford St, Boston, MA 02144, USA.

Objective: To investigate the levels and activity of matrix metalloproteinases (MMPs), myeloperoxidase (MPO) and tissue inhibitor of metalloproteinase-a (TIMP-1) in tears of eyes with Boston Keratoprosthesis type I (KPro) and to correlate these markers with the well-established prognostic hierarchy for KPro surgery. Indeed, eyes with non-cicatricial disease, chemical burns and autoimmune disease have, in this order, an increasing risk of failure following KPro implantation.

Methods: In this prospective, non-interventional cohort study, bilateral tear washes were collected from patients with KPro. Tear fluid analysis for levels of MMP-2, MMP-3, MMP-7, MMP-8, MMP-9, MMP-12, MPO, and TIMP-1 was performed using a multianalyte bead-based enzyme-linked immunosorbent assay. Total MMP activity was determined using a fluorometric assay. Correlation studies were performed between the various analytes and the underlying diagnoses leading to KPro. In eyes with unilateral KPro, MMP and MPO levels were compared between the operated and non-operated eye.

Results: Of the fourteen patients participating in this study, two had an underlying diagnosis of autoimmune disease, two had chemical burn and ten had non-cicatricial diagnoses. Eyes had received KPro at an average of 8 years (range 1 month to 17 years) prior to tear collection. MMP-9 and MPO levels were elevated in all KPro tears. When compared to eyes with non-cicatricial diseases, eyes with autoimmune disease had higher tear levels MMP-8, MMP-9 and MPO while eyes with chemical burn had higher tear levels of MMP-9 and MPO only. The MMP-8 to TIMP-1 and MMP-9 to TIMP-1 ratios were 2.4 and 1.3 times higher in eyes with KPro when compared to the contralateral eyes without KPro.

Conclusions: Our study shows that the tears of autoimmune eyes with KPro have constitutively high levels of MMPs even years after the initial insult and KPro surgery. In the presence of bilateral pathology, eyes with KPro seem to have higher MMP and MPO levels when compared to that of the contralateral non-KPro eye. The introduction of MMP inhibitors and/or additional anti-inflammatory prophylaxis may be warranted to suppress MMP activity and therefore, protect high-risk KPro eyes from corneal tissue melt.

Study supported by: Centre Hospitalier de l'Université de Montréal Fellowship Fund (MCR) Boston Keratoprosthesis Funds NEI grant EY3306 (IKG)

Conflict of interest: None

Corresponding author email address: Marie-Claude_Robert@meei.harvard.edu



- Title:** **Glaucoma Progression and Role of Glaucoma surgery in Patients with Boston Keratoprosthesis**
- Authors:** Alja Crnej, Eleftherios I. Paschalis, Borja Salvador-Culla, Allyson Tauber, Lucy Q. Shen, Claes H. Dohlman
- Affiliation:** Massachusetts Eye and Ear Infirmary, Harvard Medical School, Boston, MA, USA
- Objective:** To evaluate glaucoma onset and progression after implantation of Boston Keratoprosthesis (B-KPro) and the role of glaucoma surgery.
- Methods:** Records of patients with B-KPro implantation during 2004-2009 were reviewed. Parameters relevant to B-KPro surgery and glaucoma status were recorded. The data were analyzed in 5 groups based on the preoperative diagnosis.
- Results:** 106 eyes of 87 patients were included, average age was 54 ± 6.7 years. 46% were female. 18 eyes had B-KPro with Titanium back plate, the others with PMMA. 33 eyes were pseudophakic, the rest were left aphakic. Follow-up time was 3.3 ± 1.0 year. Indications for implantation included past infection, congenital glaucoma, trauma, autoimmune diseases, aniridia, burns, and others. 66% eyes had glaucoma preoperatively, 26% developed it de novo afterwards. Mean IOP (by finger palpation) was 16.5 ± 5.7 mmHg. Reliable visual field tests were only available in 59% of the eyes, hence cup to disc (C/D) ratio of the optic nerve head was used as main outcome measure. In B-KPro eyes with glaucoma 65% had glaucoma surgery at some point and 30% did not show progression. 31% of the total cohort had disc pallor with C/D ratio less than 0.8.
- Conclusions:** Glaucoma in B-KPro remains a challenge, despite aggressive attempts to slow its progression. Patients with glaucoma before B-KPro implantation should be considered for glaucoma surgery prior to or simultaneous with B-KPro implantation. The high number of eyes with disc pallor suggests that additional mechanisms other than elevated IOP may play a role in the optic neuropathy.

Study supported by: KPro research fund

Conflict of interest: None

Corresponding author email address: alja.crnej@gmail.com



KPro Study Group

9th KPro Meeting
April 12, 2014 Salzburg, Austria



P5

Title: A novel murine model for keratoprosthesis research

Authors: Alja Crnej¹, Masahiro Omoto¹, Thomas H. Dohlman¹, John M. Graney², Claes H. Dohlman¹ and Reza Dana¹

Affiliations: ¹ Schepens Eye Research Institute, Massachusetts Eye and Ear Infirmary, Harvard Medical School, Boston, USA; ² JG Machine, Wilmington, USA

Objective: To establish a murine model for keratoprosthesis.

Methods: A miniature keratoprosthesis (m-KPro) device was created consisting of a poly[methyl methacrylate] front part and a titanium back plate, designed after the Boston KPro, which is in widespread clinical use. BALB/c mice were used and a 2 mm in diameter donor cornea was punched out. After 2 mm trepanation of the syngeneic recipient cornea, extra-capsular crystalline lens extraction was performed. The m-KPro was assembled onto the cornea button in a similar manner to human KPro implantation. The cornea – device complex was secured to the recipient bed with eight interrupted 11-0 sutures. All mice (n=10) were followed for 8 weeks postoperatively.

Results: All m-KPro were successfully implanted and retained in all 10 animals. There were no critical complications such as endophthalmitis, corneal melting, device extrusions, leakage, extensive inflammation, or weight loss in the animals. There was mild to moderate donor and host corneal neovascularization in all cases throughout the follow-up period.

Conclusions: We have established a novel murine model of KPro implantation which mirrors clinical KPro with high fidelity. This model will allow for future studies of immuno-pathological responses to KPro implantation.

Study supported by: KPro research fund

Conflict of interest: None

Corresponding author email address: reza_dana@meei.harvard.edu



- Title:** **The MIRO KPro - a new designed one-material implant with modified surfaces: Histological evaluation of biointegration and stability in vitro, in vivo and after first clinical applications**
- Authors:** Karin Kobuch¹, Petra Eberl¹, Joachim Storsberg², Gernot Duncker³, Saadettin Sel⁴, Konrad Hille⁵, Wolfgang Müller-Lierheim⁶, Chris P. Lohmann¹
- Affiliations:** ¹Klinikum rechts der Isar, Department of Ophthalmology, Technische Universität München; ²Fraunhofer Institute Potsdam; ³Halle Institute of Ophthalmology; ⁴Heidelberg University Eye Hospital; ⁵Offenburg Eye Hospital; ⁶MIRO GmbH Munich, Germany.
- Objective:** A new type of KPro from a hydrophobic base-material and innovative local functional surface modifications by nanotechnology has been developed in order to improve biointegration, stability, optical properties and thus the long-term clinical benefit of synthetic keratoprostheses.
- Methods:** A one-piece, one-material implant from hydrophobic BENZ (HF-1)-material was designed with an optical centre of 3 mm, a haptic skirt of 3 mm and a central thickness of 3 mm. The surface of the optic and haptic part was modified corresponding to different functional requirements: optic anterior hydrophilic, optic posterior hydrophobic, haptic promoting cell adhesion and tissue integration for stable fixation. Implants have been evaluated histologically in cell culture, in animal experiments and after first clinical applications.
- Results:** All experiments showed excellent biocompatibility of the implants. In cell culture (mouse fibroblasts or corneal epithelial cells) the surface-modifications in the different areas proved to be effective and resulted in strong cell adhesion and proliferation on the haptic skirt, coated with a fibronectin-mimicking protein, whereas the optic remained clear and cell-repellent. In vivo after implantation in rabbit eyes for up to 6 weeks under stable clinical conditions the haptic part of the explants was firmly integrated into the rabbit cornea, covered by dense fibrous tissue, no signs of inflammation. The optic part was clear on both surfaces and within the material. One MIRO KPr of meanwhile 4 clinical implantations was removed after 3 years (reported separately). This human explant too showed a firm and stable anchoring of the haptic within the patient's cornea by fibrous tissue, no inflammatory tissue, clear haptic material.
- Conclusions:** By using an innovative design and nanotechniques for functional surface-modifications of the optic and haptic part and by developing special surgical techniques, the MIRO KPro gives hope to an improved biointegration and stable fixation of a fully synthetic KPro. Histological results after experimental and first clinical explantations show excellent and firm tissue adhesion without inflammatory or toxic reactions for up to 3 years. Further modifications for improvement of the optic part and the optic and cosmetic result for the patient need to be envisioned.

Study supported by: EU CRAFT-Project COOP-CT-2005-017905

Conflict of interest: Dr. Wolfgang G.K. Müller-Lierheim, MIRO GmbH, Munich, Germany

Corresponding author email address: karin.kobuch@mri.tum.de



Title: Incidence of Stevens-Johnson Syndrome and Chemical Burns to the Eye. Relevance for Keratoprosthesis Surgery

Authors: White, Michelle^{1,2}; Chodosh, James^{1,2}; Dohlman, Claes H^{1,2}

Affiliations: ¹Ophthalmology, Massachusetts Eye and Ear Infirmary, Boston, MA, USA; ²Harvard Medical School, Boston, MA, USA.

Objective: Stevens-Johnson Syndrome, Toxic Epidermal Necrolysis, Toxic Epidermal Necrolysis/Stevens-Johnson Syndrome (SJS spectrum) and alkali or acid burn of the cornea/conjunctiva (chemical burns) represent potentially devastating causes of severe corneal blindness. This study was designed to estimate the incidence and distribution of SJS spectrum and chemical burns using a large administrative claims database in the United States (US).

Methods: The 2010 Nationwide Emergency Department Sample (NEDS) database was queried for ICD-9 codes corresponding to SJS spectrum and chemical burns. The NEDS is the largest all-payer ED database in the US and contains between 25-30 million (unweighted) ED visits.

Results: As a primary diagnosis in the emergency rooms of the US in 2010, there were about 2,800 SJS spectrum and about 3,800 chemical burns. Thus, the overall incidence rate (adjusted to 2010 US population) for SJS spectrum and chemical burns were 9.1 and 12.3 cases per million people per year respectively. From the literature, approximately 30% of ocular chemical injuries and 50% of SJS spectrum result in severe vision reduction, together affecting about 2,500 people in the US per year. The mean age of patients suffering from SJS spectrum and chemical burns was 45 and 38 years, respectively. Men were more likely to suffer from chemical burns (70%) and women were more likely to suffer from SJS spectrum (55%). Distribution was equal throughout metropolitan and rural environments, as well as different regions of the US except that SJS spectrum occurred more frequently in southern US (39% of occurrences in the south vs. 17-24% in other regions).

If the US incidence rates are extrapolated to the world population in 2010, about 62,000 cases of SJS spectrum, with up to 31,000 suffering from severe vision reduction, would be expected to have occurred in 2010 worldwide. Similar extrapolations for chemical burns cannot be made since the incidence is so much higher in the developing world.

Conclusions: SJS spectrum and chemical burns affect a relatively small subset of the population but occur in younger patients, leading to a relatively high impact over the course of their lifetimes. Keratoprosthesis has had success in restoring vision in patients with SJS spectrum and chemical burns and may significantly minimize the burden of these conditions.

Study supported by: Ophthalmology, Massachusetts Eye and Ear Infirmary, Boston, MA, USA

Conflict of interest: None

Corresponding author email address: michelle_white@meei.harvard.edu



BOSTON KERATOPROSTHESIS (PART 1)

Chair: J. Barraquer, J.M. Parel

11

- Title:** Type 1 Boston Keratoprosthesis: The Ontario Experience
- Authors:** Joshua C. Teichman, Christopher W. Noel, Jordan Isenberg, Yakov Goldich, Ronan Conlon, Tessa A.I. Weinberg, Jaclyn Slomovic, Clara C. Chan, David S. Rootman, Kashif M. Baig, Allan R. Slomovic.
- Affiliation:** Toronto Western Hospital and the University of Ottawa Eye Institute, Canada
- Objective:** To report the indications, complications and solutions of all patients who underwent Boston Type 1 keratoprosthesis (KPro) surgery in Ontario, Canada, between June 2008 and July 2013.
- Methods:** A retrospective review was conducted of all keratoprosthesis procedures performed by Drs. Baig, Chan, Rootman, and Slomovic between June 2008 and July 2013. Data regarding the preoperative characteristics and intra/postoperative course of each patient was analyzed.
- Results:** Forty-five eyes were included in the study. In 32 eyes (71%), the primary indication for a KPro was failed corneal transplantation. The remaining thirteen eyes (29%) had a KPro as a primary procedure. In all eyes, preoperative visual acuity (VA) was 20/150 or worse, with 40 eyes (89%) having a VA of counting fingers, hand movement or light perception. A history of glaucoma was present in 42% of eyes. Mean follow-up time was 19 ± 14 months (range 2-57 months). The retention rate at last follow up was 96%. Best-achieved median visual acuity was 20/100 (range 20/20 - NLP), with 36% of patients achieving a VA of $>20/40$ at some point during their postoperative course. At last follow up, median VA was 20/400 (range 20/30 - NLP). The two most common complications included retroprosthetic membrane formation (23 eyes, 51%) and elevated intraocular pressure (10 eyes, 22%). Post-operatively, collagen crosslinking (CXL) was used in 1 eye to successfully manage an infectious keratitis.
- Conclusions:** This study demonstrates that the Boston Type 1 Keratoprosthesis improves visual acuity in the majority cases, and is a viable option after multiple failed grafts or in situations where there is a poor prognosis for traditional penetrating keratoplasty. In addition, this study shows that CXL is a potential management option in patients with infectious keratitis following Boston Type 1 Keratoprosthesis surgery.

Study supported by: N/A

Conflict of interest: None

Corresponding author email address: josh.teichman@gmail.com



KPro Study Group

9th KPro Meeting
April 12, 2014 Salzburg, Austria



12

Title: **Complications and Retention Rate of Threadless Type I Boston Keratoprosthesis in eastern Province of Saudi Arabia**

Author: Al-Arfaj K

Affiliation: University of Dammam, Dammam, Kingdom of Saudi Arabia

Objective: To evaluate the visual outcomes, complications and retention rate of threadless type I Boston Keratoprosthesis in eastern province of Saudi Arabia

Methods: Retrospective analysis of four eyes of 18 patients who underwent Boston type I threadless Keratoprosthesis (KPro) implantation between January 2009 and December 2013.

Results: In the median follow up of 43 months (range 3 to 60 months), visual outcomes were satisfactory. Operative diagnosis included 10 patients of post-trachoma dense vascularized corneal scarring, one patient with Ocular cicatricial pemphigoid one patient of corneal alkali burn and 6 patients of repeated failed corneal grafts. All patients demonstrated significant improvement in vision; with pre-operative best corrected visual acuity (BCVA) of 20/200 to 20/40 on their last follow-up visits. Complication includes corneal melting, glaucoma and retro-prosthetic membrane.

Conclusions: Consistent with earlier reports from other parts of the world, all the 4 eyes had a significant increase in vision after Boston type I KPro implantation. However, patients require close follow-p to manage any complications.

Study supported by: University of Dammam, Dammam, Kingdom of Saudi Arabia

Conflict of interest: None

Corresponding author email address: kmarfaj@gmail.com



KPro Study Group

9th KPro Meeting
April 12, 2014 Salzburg, Austria



13

- Title:** Polish Experience with Boston Type I Keratoprosthesis
- Authors:** Edward Wylegala, Dariusz Dobrowolski, Anna Nowińska
- Affiliation:** II Ophthalmology Clinic, Medical University of Silesia, Dept. of Ophthalmology, District Railway Hospital, Panewnicka 65 st., 40760 Katowice, Poland
- Objective:** Efficacy of Keratoprosthesis (KPro) implantation in polish patients.
- Methods:** 6 patients underwent KPro surgery between March 2010 and May 2011 with a follow-up at least 32 months. Three of them underwent series of failed penetrating keratoplasties (PK), another 3 persons were disqualified from PK due to limbal deficiency caused by chemical burns. We analysed visual acuity (VA), anatomic success and complications.
- Results:** Pre-op VA varied from light perception to counting fingers. After surgery VA improved to 0.1, 0.2 and 0.5 in 3 patients, light perception was still in 1 eye, 2 patients lost vision due to untreatable glaucoma. Four patients suffered from glaucoma before surgery, one developed glaucoma after surgery.
- Conclusions:** Keratoprosthesis should be considered as a surgery of choice in patients who have high risk of PK failure despite of serious risk of postoperative glaucoma progression.
- Study supported by: N/A
- Conflict of interest: None
- Corresponding author email address: dardobmd@wp.pl



- Title:** Results of Boston Type I KPro in Barcelona and Salzburg
- Authors:** Orang Seyeddain², Jurja Rosandic¹, Maria Fideliz de la Paz¹, Josef Stoiber², Juan Alvarez de Toledo¹, Günther Grabner², Rafael I. Barraquer¹, Ralph Michael¹
- Affiliations:** ¹Centro de Oftalmología Barraquer, Barcelona, Spain; ²Department of Ophthalmology, Paracelsus Medical University, Salzburg, Austria.
- Objective:** To describe the outcome of patients with Boston Type 1 keratoprosthesis, regarding anatomical and visual success and complications.
- Methods:** Retrospective case series of patients, who underwent Boston type I keratoprosthesis surgery at the Centro de Oftalmología Barraquer in Barcelona and at the University Eye Clinic in Salzburg between May 2006 and February 2013. 67 eyes were included. Anatomical success, visual acuity and complication rate were evaluated and correlated with the initial diagnosis. The follow-up period was at least three months.
- Results:** The mean age of patients was 54 years, 62% were male and 38% were female. 11 patients underwent Type I Boston Kpro implantation as a primary procedure, while the other 52 patients had previous graft failure. The most frequent diagnoses were autoimmune diseases (16 eyes), severe chemical or thermal burn (12 eyes), leukoma post infectious keratitis (7 eyes) and bullous keratopathy (6 eyes). The mean follow-up time was 26 months. Retention of the prosthesis was achieved in 95% at one year and 78% at 4.5 years. The outcome of the autoimmune cases was similar to the group with “other diagnoses” and better than those with chemical/thermal burn. The most frequent complication was development of a retroprosthetic membrane. Visual acuity (LogMar) in the chemical/thermal burn group was 2.30 preoperatively, 0.69 at one year, 0.52 at two years and 0.39 at three years; in the autoimmune group visual acuity was 2.3 preoperatively, 0.65 at one year, 0.15 at two years, and 1.5 at three years.
- Conclusions** Most cases showed improvement in VA after Boston Type 1 keratoprosthesis. Posterior segment complications and infections mostly resulted in persistent loss of vision. These complications should be prevented and carefully treated.

Study supported by: N/A

Conflict of interest: None

Corresponding author email address: o.seyeddain@salk.at



Title: Boston type 1 keratoprosthesis outcomes and complications: results from the Zhongshan Ophthalmic Center

Authors: Jianjun Gu, Jiajie Zhai, Yingfeng Shao, Jiaqi Chen

Affiliation: Corneoplastic Unit, Zhongshan Ophthalmic Center, Sun Yat-sen University, Guangzhou 510060, PR China

Objective: To report the outcomes of the Boston Type 1 keratoprosthesis surgery (BKPro) in the visual rehabilitation of patients with corneal blindness at our institution.

Methods: A retrospective chart review of 17 eyes of 17 patients who had undergone BKPro surgery at the Zhongshan Ophthalmic Center, between 2009 and 2012. Outcome measures included visual acuity, retention rates, and complications.

Results: A total of 17 patients, with age ranging from 30 to 61 years (mean 43 (SD 10.4) years), were included in the analysis. The preoperative diagnoses were severe chemical burns (n=16, or 94%), and Stevens-Johnson syndrome (n=1, or 6%). Follow-up ranged from 6 months to 53 months (mean 28.5 (SD 9.2) months). Anatomic retention rate during the entirety of the follow-up period was 88% (15 of 17 eyes). Retention failure occurred 20 months after BKPro implantation in 1 eye with chemical burns. It was due to retinal detachment and silicone oil leakage between the stem and corneal graft. The second patient with chemical burns developed melting around the BKPro stem 6 months post-operation. Both eyes had tectonic penetrating keratoplasty and vision acuity declined to HM. Preoperative best-corrected visual acuity (BCVA) ranged from hand movement to light perception. At last follow-up for all eyes, 10 eyes (58.8%) achieved BCVA \geq 20/200. Postoperative complications include retroprosthetic membrane formation (41.2%), elevated intraocular pressure (41.2%), retinal detachment (5.9%), and overgrowth of mucous membrane over the optical cylinder (11.8%).

Conclusions: Boston KPro surgery provides visual recovery for eyes with end-stage ocular surface disease, but postoperative glaucoma can be difficult to manage and require frequent follow-up to monitor.

Study supported by: Funding of Science and Information Technology of Guangzhou (No. 2010GN-E00221)

Conflict of interest: None

Corresponding author email address: docjiaqi@163.com (Jiaqi Chen)



KPro Study Group

9th KPro Meeting
April 12, 2014 Salzburg, Austria



16

- Title:** **Boston keratoprosthesis in autoimmune disorders**
- Authors:** James Chodosh
- Affiliation:** Massachusetts Eye and Ear Infirmary, Harvard Medical School, Boston, MA, USA
- Objective:** To describe Boston keratoprosthesis outcomes in patients with severe ocular surface damage secondary to autoimmune disorders.
- Methods:** Review of published methodologies and outcomes of Boston keratoprosthesis implantation in the setting of autoimmune disorders.
- Results:** Perioperative care and device design has evolved over the last 15 years, and recognition of appropriate indications for the Boston type I versus the Boston type II (through the eyelid) keratoprosthesis increased, leading to improved outcomes. For patients with Stevens Johnson syndrome/toxic epidermal necrolysis, the retention of ambulatory vision (> 20/200) after Boston keratoprosthesis implantation improved from zero at 5 years after surgery to approximately 50%. For patients with mucous membrane pemphigoid, the Boston type II keratoprosthesis was shown to offer better long term outcomes than the Boston type I device.
- Conclusions:** Improvements in the perioperative care, design modifications to the device, and better understanding of when to use a specific device type have improved outcomes for the Boston keratoprosthesis for corneal blindness in the setting of autoimmune disorders.
- Study supported by:** Research to Prevent Blindness, NY, NY
- Conflict of interest:** The author is an employee of the Massachusetts Eye and Ear Infirmary, where the Boston keratoprosthesis is manufactured.
- Corresponding author email address:** james_chodosh@meei.harvard.edu



17

KEYNOTE LECTURE:

THE INFANT KPRO: TEAM, LOGISTICS AND RESULTS WITH SURGICAL TECHNIQUES AND POSTOPERATIVE MANAGEMENT

- Author:** James V. Aquavella
- Affiliation:** University of Rochester Flaum Eye Institute, Rochester, NY, USA
- Objective:** To describe the elements of the multidisciplinary team approach considered essential to the success of infant keratoprosthesis.
- Methods:** We reviewed our decade of experience in data collection, family interaction, establishing protocols, disseminating information, obtaining prior authorization, satisfying institutional financial requirements, cooperating with referring physicians and institutions, assembling our team, providing travel and lodging assistance, ordering supplies, scheduling surgery, providing follow-up, and monitoring postoperative care.
- Results:** The demands of this surgery in this population are numerous and the appropriate and satisfactory procedures required many months to develop and implement. Intake and eligibility determination, obtaining medical records, establishing postoperative local follow-up arrangements, coordinating institutional financial considerations, coordinating pediatric, anesthesia, cornea, glaucoma, and vitreoretinal evaluation, surgical scheduling, establishing surgical plan, travel and lodging arrangements, postoperative planning, and definitive follow-up. Allowance for urgent examination and surgical intervention in the event of complications is an important aspect since the various subspecialists must be available. Staff must be assigned to initiate and coordinate all aspects of the arrangements in a timely fashion.
- Conclusions:** This type of surgery should be performed only when there is a reasonable expectation that family, surgical team, nursing, and support staff can be made available from the initial diagnosis through years of follow-up, including the management of unforeseen complications. Long term functional acuity can be maintained in most infants and the provision of even limited sight cannot be overestimated.
- Study supported by:** N/A
- Conflict of interest:** None
- Corresponding author email address:** james_aquavella@urmc.rochester.edu



OTHER AND NEW KPRO'S

Chair: C. Dohlman, M. De La Paz

18

- Title:** Russian KPro's: Types, Technique and Results
- Authors:** Moroz Z, Malyugin B, Golovin A, Vlasova V.
- Affiliation:** S. Fyodorov Eye Microsurgery State Institution, Moscow, Russia.
- Objective:** To evaluate the results of combined Russian KPro (Fyodorov-Zuev model) implantation and anterior chamber reconstruction in patients with adherent vascular burn leucomas.
- Methods:** Russian KPro's were implanted in 87 patients (87 eyes). All patients underwent routine preoperative evaluations including ultrasonography, anterior segment OCT and electrophysiological testing pre and postoperatively (from 1 month up to 5 years). Preoperative BCVA varied from light projection to 0.01. Surgical procedure consisted of corneal trephination, anterior chamber reconstruction by synechiotomy (87.4%), cataract extraction (40.2%), anterior vitrectomy (40.2%), iridoplasty (37.9%), Ahmed valve (mod. FP7) implantation (29.9%), followed by UV cross-linked donor cornea with pre-implanted KPro suturing to the recipient's bed.
- Results:** BCVA improved from 0,001 up to 1.0. During the 1st month no post-op complications were detected. After the 6th months of observation following complications were observed: retroprosthetic membrane (26.4%), IOP decompensation (19.6%), corneal necrosis (13.9%), retinal detachment (4.6%). Within 3 years the main complication was aseptic stromal necrosis (59.8%), leading to partial KPro footplate protrusion. This complication was treated by covering the cornea with buccal mucosa (50%), autoconjunctival graft (35%) or lamellar grafting with donor cornea (15%). The total number of the above-mentioned procedures for 52 patients was 104. Finally, in 3 years time 18 KPro's were removed (20.7%).
- Conclusions:** The results of «UV cross-linked donor cornea - Russian KPro» implantation combined with complex anterior segment reconstruction in patient with adherent burn vascular leucomas allowed to achieve KPro retention in 79.3% of cases.
- Study supported by:** N/A
- Conflict of interest:** None
- Corresponding author email address:** golovinmntk@gmail.com



Title: The fully synthetic MIRO KPro - Report on development, animal experiments, and initial clinical results

Authors: Gernot LW. Duncker¹, Konrad Hille², Karin Kobuch³, Wolfgang Müller-Lierheim⁴, Saadettin Sel⁵, Joachim Storsberg⁶

Affiliations: ¹Halle Institute of Ophthalmology, ²Offenburg Eye Hospital, ³ Munich University Eye Hospital Rdl, ⁴MIRO GmbH, Munich, ⁵Heidelberg University Eye Hospital, ⁶Fraunhofer Institute Potsdam, Germany.

Objective: To clarify the feasibility and safety of a new fully synthetic keratoprosthesis ensuring enhanced biocompatibility

Methods: The MIRO KPro is made of a commercial available hydrophobic copolymer. The haptic is coated with a special protein which signals keratocytes and fibroblasts to latch on to the implant, anchoring it to the eye but leaving its optical centre clear. The surface of the optical part is modified chemically to be hydrophilic. So it can be wetted by the tear film. The implantation technique, rabbit experiments and initial clinical results are demonstrated. Light and electron microscopy pictures of explanted MIRO KPros are presented.

Results: Firm adhesion of the keratoprosthesis could be achieved in nearly all cases. The survival rate is now up to three years and remains stable. Firm anchorage of the KPro was achieved by a coat of the haptic promoting growth of cells and deposition of extracellular matrix in connection with a ring-shaped jacket of corneoscleral donor tissue.

Conclusions: Despite aiming at an improved surface of the optic, the quality of the optic, especially the back surface quality was worse than in conventional PMMA KPros. Further research is necessary to really improve the surface quality of the MIRO KPro.

Study supported by: EU grant

Conflict of interest: None

Corresponding author email address: gernot.duncker@googlemail.com



Title: Biosynthetic corneal collagen implants - report on ex vivo, in vivo and clinical experiences - EU-Nanomed I-Care Project

Authors: Kerstin Wand¹, Raphael Neuhann¹, Andrea Ullmann¹, Katharina Plank¹, Michael Baumann², Roland Ritter³, Kimberley Merrett⁴, M. Mirazul Islam⁵, May Griffith⁵, Chris P. Lohmann¹, Karin Kobuch¹

Affiliations: ¹Klinikum rechts der Isar, Department of Ophthalmology, Technische Universität München, Munich; ²MLase AG, Germering München, Munich; ³Technolas PV Bausch&Lomb, Munich, Germany, ⁴University of Ottawa Eye Institute and Research Institute, Ottawa, Canada; ⁵Integrative Regenerative Medicine Centre and Dept. of Clinical and Experimental Medicine Linköping University, Linköping, Sweden

Objective: To develop and evaluate new biosynthetic corneal collagen III implants and a new sutureless surgical implantation technique by performing a deep anterior lamellar keratoplasty by excimer or femtosecond laser and fixation of implants in the corneal bed by riboflavin-UVA crosslinking

Methods: A range of cell-free corneal implants consisting of recombinant human collagen type III were examined. Ex vivo the biosynthetic corneal implants were placed on the anterior cornea of porcine and rabbit eyes after performing deep anterior lamellar keratoplasty with either femtosecond or excimer laser. Riboflavin-UVA crosslinking was then performed with isotonic or hypotonic riboflavin at either standard (3mW/cm² for 30 minutes) or rapid (18mW/cm² for 5 minutes) procedure. In vivo the biosynthetic implants were implanted the same way into eight rabbit eyes followed by an amniotic membrane transplantation and a tarsorrhaphy, which remained for two weeks. For examination the corneas were excised, fixed in PFA4% and embedded in paraffin. Crosslinking effects on the implants (especially thickness) and the adhesion between implant and corneal bed were evaluated by slitlamp biomicroscopy, OCT images and histologically (HE-stained/ picrosirius stained sections, electronmicroscopy).

Results: After crosslinking procedure the implants showed different degrees of thinning and in vivo even degeneration. The accuracy of cutting the corneal bed was highest with the excimer laser due to docking problems with the femtosecond laser, especially in our in vivo trials. Good adhesion of the implant in the corneal bed after crosslinking could be demonstrated in OCT images. This was more accurate in porcine eyes than in rabbit eyes. Histologically crosslinks between implant and corneal stroma were demonstrated. There was no difference between standard and rapid crosslinking procedure.

Conclusions: The combination of performing a deep anterior lamellar keratoplasty with excimer or femtosecond laser plus riboflavin-UVA crosslinking as an alternative fixation method for biosynthetic corneal collagen implants was demonstrated to be promising. It can reduce suture-related complications as haze formation and surface irregularity. Stability of the implants, especially shrinkage and degeneration after riboflavin-UVA crosslinking, as well as laser accuracy, especially optimizing the docking procedure, needs to be further evaluated.

Study supported by: EU Nanomedicine ERA-net project I-Care, with funding from VDO to MLase AG, Swedish Research Council to MG

Conflict of interest: M. Baumann works for MLase AG; R. Ritter works for Technolas B&L.

Corresponding author email address: karin.kobuch@mri.tum.de



KPro Study Group

9th KPro Meeting
April 12, 2014 Salzburg, Austria



21

Title: My Belgian experience in Keratoprosthesis

Authors: Bernard Bernard Duchesne¹, Pierre Sohngen¹, Yves Gillon², Gaël Xhaufaire¹

Affiliations: ¹Department of Ophthalmology and ²Department of Oro-Facial surgery, University of Liège, Belgium

Objective: To share our experience, managing difficult cases of corneal blind condition by different types of KPro. 3 Keralia, 9 Boston KPro type 1, 9 modified osteo-odonto-keratoprosthesis (MOOKP), 2 osteo-keratoprosthesis (OKP) have been performed in our center since 2004.

Methods: The mainstream in KPro's choice is to distinguish dry eye and inflamed conditions to differentiate between 2 patient categories. Dry eye or inflamed eyes will have MOOKP if possible or OKP if there is no tooth available. Corneally blind patient with wet eye will undergo Boston KPro surgery. As one reference center for the Keralia we started and stopped using that prosthesis due to 100% extrusion rate.

Results: Even if the surgery is a lot easier with the Boston KPro, we have a higher incidence rate of complication compared to MOOKP patients. Depending on criteria retained such as anatomical success rate, or functional success rate; results will be discussed.

Conclusions: Our series is obviously too small for any conclusion but we have the feeling that MOOKP is, in our hands, the technique of choice for corneal blind patients. The surgery is evidently very heavy for the patient, for the team and has to be supported financially by the hospital.

Study supported by: N/A

Conflict of interest: None

Corresponding author email address: B.Duchesne@chu.ulg.ac.be



KPro Study Group

9th KPro Meeting
April 12, 2014 Salzburg, Austria



22

- Title:** A new type of temporal keratoprosthesis on the drawing board
- Author:** Anastasios C Charonis
- Affiliation:** Athens Vision Eye Institute, Greece
- Objective:** To describe a new intrasurgical Kpro, a new Excimer laser mask that facilitate a new way to perform cataract surgery, iridoplasty, secure and suture a PKP graft on to the recipient cornea
- Methods:** A two minute animation video has been prepared that demonstrates the procedure
- Results:** The device(s) mentioned in the presentation have not reached any clinical significance
- Conclusions:** A lasik like PKP procedure may be applicable to patients in the near future
- Study supported by:** AthensVision Institute
- Conflict of interest:** Anastasios Charonis is the inventor of the Eyeolck, the AVisc devices and the Trick suturing concepts
- Corresponding author email address:** anastasioscharonis@athensvision.gr



NEW CLINICAL AND EXPERIMENTAL STUDIES

Chair: Z. Moroz, J. Stoiber

23

Title: Effectiveness of immobilized antimicrobial peptide for preventing perioperative corneal implant associated infection

Authors: Xiao Wei Tan¹, Gwendoline Goh¹, P Saraswathi², Chan Lwin Nyein¹, Melina Setiawan¹, Andri Riau¹, R Lakshminarayanan², Donald Tan^{3,4,5}, Roger W. Beuerman^{2,3,6}, Jodhbir S. Mehta^{1,3,4,5}

Affiliations: ¹Tissue Engineering and Stem Cell Group, ²Ocular Proteomics Group, Singapore Eye Research Institute, Singapore 168751; ³Yong Loo Lin School of Medicine, National University of Singapore, Singapore 117597; ⁴Singapore National Eye Centre, Singapore 168751; ⁵Duke-NUS Graduate Medical School, Singapore 169857; ⁶Duke-NUS SRP Neuroscience and Behavioral Disorders, Singapore 169857.

Objective: Artificial kerato-prosthesis is prone to microbiological assault after implantation. Here we aimed to improve the bactericidal effect of a device implanted into the cornea by cross linking an antimicrobial peptide to its surface.

Methods: SESB2V antimicrobial peptide (AMP) was bound onto the surface of Ti via crosslinking with polydopamine. Chemical binding was assessed with attenuated total reflectance–fourier transform infrared spectroscopy (ATR-FTIR) and X-ray photoelectron spectroscopy (XPS). The functionalized substrates were examined for the abilities to enhance primary human corneal fibroblast adhesion, proliferation and viability while bactericidal assay was carried out to evaluate the anti-microbial activities of immobilized SESB2V peptide. A corneal stroma pocket was created by a femtosecond laser. Ti implants were inserted into the pocket through a small corneal incision. *S. aureus* and *P. aeruginosa* were then inoculated into the pocket. The implanted corneas were examined through slit lamp observation and anterior segment optical coherence tomography (AS-OCT). After two days of infection, rabbit cornea tissue was collected for haematoxylin and eosin (H&E) staining. Inflammatory cellular response was also evaluated by immunostaining with inflammatory cell markers.

Results: We found that Ti implants that functionalized with SESB2V had enhanced corneal cell proliferation and anti-microbial properties in vitro. Moreover, there was a lower incidence and less extent of infection on rabbit corneas implanted with Ti-AMP than those corneas with pristine Ti implants. Histological analysis revealed that less inflammatory cells were found in the cornea pocket tissue with the AMP coated Ti implants compared with pristine Ti.

Conclusions: SESB2V AMP significantly improved the bactericidal effect of Ti discs. This would further expand the usage of AMP coating in the development of keratoprosthesis device and to prevent keratoprosthesis surgery related infection.

Study supported by: Singapore Shaw's foundation R684, Singhealth research foundation R834

Conflict of interest: None.

Corresponding author email address: jodmehta@gmail.com



Title: Investigating the relationship between surface quality and biofilm formation in explanted KPros using confocal microscopy

Authors: Heather Durkee¹, Shawn Kelly¹, Darlene Miller², Mariela Aguilar¹, Guillermo Amescua², Victor Perez², Yoh Sawatari³, Aleksandra Rachitskaya², Audina Berrocal², Eduardo Alfonso², Jean-Marie Parel^{1,2}

Affiliations: ¹Ophthalmic Biophysics Center and ²ABLEH, Bascom Palmer Eye Institute and ³Dept of Maxillofacial Surgery, Univ. of Miami Miller School of Medicine, Miami, FL, USA.

Objective: To investigate the relationship between surface roughness of keratoprotheses and biofilm adherence.

Methods: Five explanted keratoprotheses (3 Boston Type I, 1 Boston Type II, 1 Modified Osteo Odonto Keratoprothesis) were imaged with a Leica 5PS confocal microscope with 5x, 20x, and 63x objective lenses. The biofilm and bacteria was visualized with BacLight Live/Dead assay (L13152, Invitrogen) and the surface features were visualized using bright field illumination. In a second experiment, poly(methyl methacrylate) optical cylinders (n=3) were fabricated to mimic the shape of a KPro optical cylinder. Each optical cylinder had a different surface quality (i.e. unpolished, semi-polished, polished). The initial quality of the mock optical cylinders was assessed by bright field imaging on the confocal microscope. Next, the mock optical cylinders were placed in a CDC biofilm reactor along with Staphylococcus epidermidis and thioglycollate in dextrose media. The mock optical cylinders were removed after 96 hours and stained with the BacLight Live/Dead assay. Microbial adherence and biofilm formation was visualized with confocal microscopy.

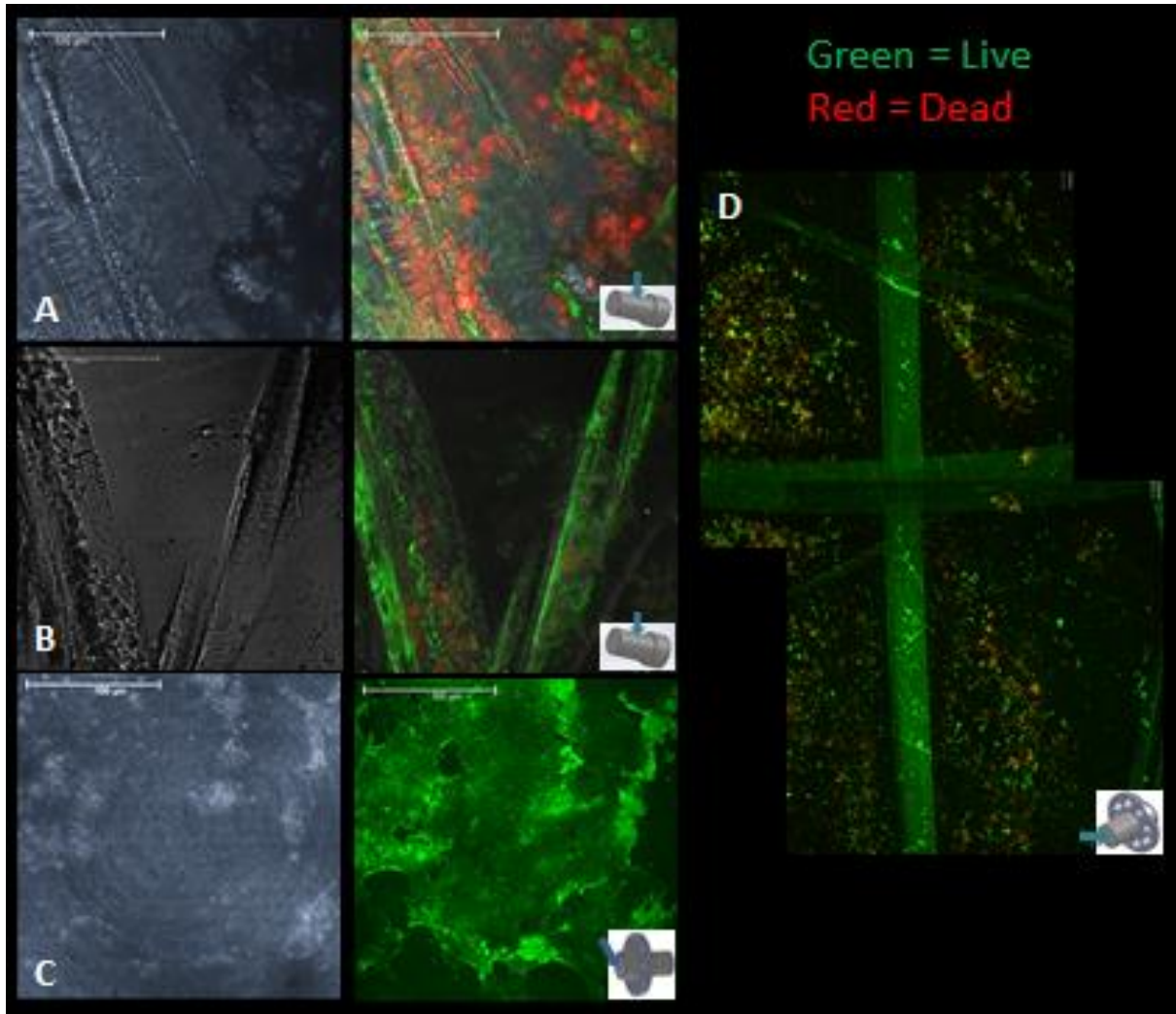
Results: Machining marks and surface scratches were present on the surfaces of all KPros. Biofilm was present on the KPros and more concentrated in the areas with surface defects. The mock optical cylinder experiment demonstrated increased microbial adherence and biofilm formation on the less polished surfaces.

Conclusion: Irregular surface characteristics of the KPros created during fabrication and implantation allowed for more bacterial and biofilm adherence, as observed by confocal microscopy. Improving surface quality of the KPro may decrease the areas where bacteria and biofilm can adhere to the mesoplant. The poor surface quality of the implants may provide an environment within the eye where microbes can flourish, which may lead to postoperative complications such as endophthalmitis.

Study supported by: USAMRMC Department of Defense W81XWH-09-1-0674; Florida Lions Eye Bank; NIH Center Grant P30EY14801; an unrestricted grant from Research to Prevent Blindness; Henri and Flore Lesieur Foundation (JMP).

Conflict of interest: None

Corresponding author email address: hdurkee@med.miami.edu jmparel@med.miami.edu



Left: (A) Confocal microscopy images of scratches on cylindrical face of MOOKP; (B) deep scratch in cylindrical face of MOOKP with bacteria deposit in crevices; (C) center anterior optical face of Boston Type 1 KPro with organic matter deposits; (D) mark on posterior face of optic

Right: Confocal microscopy images of the optical cylinders after 96 hours in the biofilm reactor



KPro Study Group

9th KPro Meeting
April 12, 2014 Salzburg, Austria



25

Title: One touch femtosecond laser KPro

Authors: Luca Menabuoni¹, Alex Malandrini¹, Annalisa Canovetti¹, Ivo Lenzetti¹, Francesca Rossi², Heather Durkee², Roberto Pini²

Affiliations: ¹U.O. Oculistica, Azienda Asl 4 Prato, Ospedale Misericordia e Dolce, Prato, Italy
²Istituto di Fisica Applicata "Nello Carrara", Consiglio Nazionale delle Ricerche, Florence, Italy

Objective: To prevent decentration of the visual axis of the Boston Keratoprosthesis by making two concentric trephinations using a femtosecond laser.

Methods: Five selected patients underwent Boston Keratoprosthesis surgery. The donor corneas were prepared using a femtosecond laser iFS150TM (Abbott Laboratories Inc. Abbott Park, Illinois, USA). In the same applanation procedure, two concentric side cuts were made on the anterior surface of the donor cornea: the first cut had an 8.7 mm diameter and the second cut had a 3.0 mm diameter. The resulting donor cornea was cut to the proper dimensions and the inner diameter precisely matched with the dimensions of the prosthesis. The surgery was concluded with standard KPro procedure.

Results: At the end of the surgery, the KPro was properly centered. During a 2 year follow up, OCT analysis showed the epithelium growing on the prosthesis for a length of about 3-4 mm. Accurate centration of the optical prosthesis within the donor carrier cornea created a satisfactory barrier against bacteria and possible infections. No adverse inflammatory reactions were observed. The two year follow up evidenced that good flap apposition and KPro centration was maintained.

Conclusions: Preparation of the donor cornea using the one touch femtosecond laser procedure is an easy and safe procedure that produces a more stable and centered KPro graft.

Study supported by: MILoRDS – Minimally Invasive Laser in Robots for Diagnosis and Surgery Project granted by the Tuscany Region (Italy) -PAR FAS 2007-2013.

Conflict of interest: None

Corresponding author email address: f.rossi@ifac.cnr.it



Title: **In Vitro and In Vivo Assessment of Titanium Surface Modification for Coloring the Backplate of the Boston Keratoprosthesis**

Authors: Eleftherios I. Paschalis, James Chodosh, Sandra Spurr-Michaud, Andrea Cruzat, Allyson Tauber, Irmgard Behlau, Ilene Gipson, and Claes H. Dohlman

Affiliation: Massachusetts Eye and Ear Infirmary / Harvard Medical School, Boston, MA, USA

Objective: Recent use of a titanium (Ti) backplate has improved the design and biocompatibility of the Boston Keratoprosthesis (BKpro). Titanium's shiny metallic appearance, however, makes the cosmetic outcome less favorable. The purpose of this study was to develop and test a coloring surface modification of Ti.

Methods: Ti coloring was achieved using electrochemical anodization. Color assessment included scanning electron microscopy, atomic force microscopy (AFM), x-ray diffraction crystallography (XRD), and Fourier transform infrared spectroscopy (FTIR). Biocompatibility assessment of Ti disks included in vitro proliferation and cytotoxicity in co-culture with human corneal limbal epithelial (HCLE) cells, primary human corneal fibroblasts, and immortalized human corneal endothelial cells (HCEnCs), and in vivo intralamellar implantation in rabbit corneas. Histologic appearance (hematoxylin-eosin and trichrome staining) and presence of cell inflammation (CD45), apoptosis (TUNEL), and corneal neovascularization (CD31) were evaluated 27 and 53 days post implantation.

Results: Blue and brown coloration of Ti was achieved. Analysis showed the presence of a nanoporous oxide surface with no chemical change of the modified Ti surface. In vitro assessment showed no significant differences in cell proliferation and cytotoxicity between anodized and non-anodized Ti ($P > 0.05$; ANOVA for all cell types). Analysis of corneal tissues harboring the Ti disks showed normal cellular appearance, and lack of CD45, TUNEL, and CD31-positive cells.

Conclusions: A biocompatible Ti backplate coloring was achieved by electrochemical anodization. In vitro and in vivo results suggest that the anodized Ti is equally biocompatible and as safe as the standard non-anodized Ti. The color modification of the Boston KPro may improve the cosmesis and acceptance of the BKpro by patients.

Study supported by: Boston Keratoprosthesis Fund

Conflict of interest: None

Corresponding author email address: ep@meei.harvard.edu



Title: Use of Intraocular Video Endoscopic Examination in the Preoperative Evaluation of Keratoprosthesis Surgery to Assess Visual Potential

Authors: Amescua G^{1,2}, Farias CC^{2,3}, Ozturk HE², Albin TA¹, Berrocal AM¹, Betancurt C², Parel JM^{1,3}, Oliveros MC⁴, Gibbons A², Vargas JM⁴, Perez VL^{1,2}.

Affiliations: ¹Department of Ophthalmology, ²Ocular Surface Center of Excellence and ³Ophthalmic Biophysics Center, Bascom Palmer Eye Institute, University of Miami Miller School of Medicine; Miami, FL, USA; ⁴Department of Ophthalmology, Cornea Service, Centro Oftalmologico de Valencia; Valencia, Venezuela.

Objective: To determine the clinical utility of intraocular video endoscopy examination for the evaluation of the posterior segment in patients being considered for a Boston Type I Keratoprosthesis (KPro).

Methods: Interventional case series study of ten patients with a history of corneal blindness caused by failed penetrating keratoplasty (PK) and inability to accurately assess visual potential were included in this study. Ophthalmological examination, B-scan ultrasonography and pars-plana video-endoscopy was carried out to assess the retina and optic nerve before KPro.

Results: Posterior segment examination was successfully used to evaluate the retina and optic nerve of all patients with opaque corneas. Out of 10 patients that underwent endoscopic examination, 3 (30%) were considered to be adequate candidates for KPro surgery, and 7 (70%) were not. This was based on visualized retinal disease and/or optic nerve pathology. Of the 3 patients that underwent KPro surgery, all of them had a significant improvement of vision, including: counting finger to 20/100; hand motion to 20/50; light perception to 20/80; as suggested by the endoscopy preoperative exam. No complications of the endoscopy procedure were observed.

Conclusions: This report demonstrates the successful use of intraocular video endoscopy to rule out threats to a good visual outcome of patients being considered candidates for KPro. Direct visualization of the posterior segment can be part of the pre-operative algorithm in the decision process of performing a KPro surgery in patients when visual potential is questionable.

Study supported by: USAMRMC Department of Defense Grant#W81XWH-09-1-0675, NIH Center Core Grant P30EY014801; Unrestricted grant from Research to Prevent Blindness

Conflict of interest: None

Corresponding author email address: gamescua@med.miami.edu



POSTER ORAL PRESENTATION (PART 2)

3 slides and 3 minutes each with 1 Question

Chair: E. Wylegala, C. Forlini

P8

- Title:** Alkali Burn to the Eye: Protection using TNF- α inhibition
- Authors:** Eleftherios I. Paschalis, Harry Sweigard, Fabiano Cade, Alja Crnej, James Chodosh, Demetrios G. Vavvas, Kip Connor, Reza Dana, Claes H. Dohlman.
- Affiliation:** Massachusetts Eye and Ear Infirmary / Harvard Medical School, Boston, MA, USA.
- Objective:** To evaluate the mechanism of retinal damage after ocular surface alkali burns, and the protective effect of TNF- α blockade and corticosteroids.
- Methods:** Alkali injury was induced in mouse and rabbit corneas using NaOH. Mice burns were performed by placing a 1 mm² filter paper soaked in 1N NaOH on the cornea for 15 seconds, and in rabbits, by placing a trephine on the cornea, filled with 2N NaOH for 1 minute. Copious irrigation with saline solution was performed for 15 minutes after the burns. In vivo pH measurements were performed in the anterior chamber (AC), vitreous and suprachoroidal space in anesthetized rabbits during the first 24 hours after the burn. Ocular damage was assessed with TUNEL assay, and immune cell infiltration was assessed with CD45 immunolocalization. Retinal IL1- β , IL2, IL6, TNF- α , CCL5, and MIP-1 α levels were measured in mice 24 hours after the burn using enzyme-linked immunosorbent assay (ELISA). RT-PCR was used to quantify the gene expression of TNF- α , TNFR I and TNFR II in whole mice retinas and in distinct retinal layers (retina ganglion cell layer, inner and outer nuclear layers) isolated using laser capture micro-dissection. Anti-TNF- α antibody, corticosteroids, or both were administered intraperitoneally (IP) or subcutaneously, to abrogate the retinal damage after the burn. Immunoglobulin G (IgG) was administered as control.
- Results:** In rabbit eyes, pH in the suprachoroidal and vitreous body remained unchanged 24 hours after corneal burns in rabbits, while AC pH exhibited marked elevation within seconds. Significant cell apoptosis was present in all anterior structures (cornea, iris, uvea) within 24 hours after the burn. In addition, polymorphonuclear leukocytes infiltration was evident in the epiretinal layer. In contrast, mice eyes exhibited significant damage in both the anterior and posterior segments within 24 hours after corneal burn, when 80% of the retinal ganglion cells (RGC) were TUNEL positive, and CD45+ cells infiltration in the RGC and epiretinal layer within 24 hours after the burn. There was a 10-fold increase in the retinal inflammatory cytokines in the NaOH-treated groups compared to controls. In mice, retinal TNF- α gene expression was unchanged 24 hours after the burn, while TNFR I and TNFR II gene expressions expression was increased 2-fold. mRNA analysis of each retinal layer showed TNFR I gene upregulation only in the inner nuclear layer (INL). This was unaffected by anti-TNF- α therapy. However, a single dose of anti-TNF- α antibody, administered 15 minutes after the burn, markedly reduced retinal TUNEL staining, CD45+ cell infiltration, and inflammatory cytokine expression compared to controls. TNF- α blockade combined with corticosteroid infusion was synergistic, and provided further retinal protection after alkali burn, and marked reduction in corneal neovascularization, and TUNEL staining and CD45+ cell infiltration.
- Conclusions:** This study shows that alkali corneal burns elicit significant retinal damage in mice within 24 hours. Alkali diffusion posteriorly was not seen in rabbits. Thus, retinal damage in larger eyes is likely mediated by posterior diffusion of inflammatory cytokines, e.g., TNF- α . Our results suggest that inflammatory cytokines affecting the retina may be generated in the anterior eye. Further supporting this theory is the lack of TNF- α gene upregulation in the retina and the marked upregulation of TNFR I and II genes post burn. A single dose of anti-TNF- α antibody, administered 15 minutes after the burn, provided significant retinal and corneal protection. The combination of anti-TNF- α and corticosteroids appeared synergistic, and may provide increased protection in severe burns. This study could lead to novel therapy for alkali injured patients.

Study supported by: Boston Keratoprosthesis Fund

Conflict of interest: None

Corresponding author email address: ep@meei.harvard.edu



Title: A Novel Implantable Glaucoma Valve Using Ferrofluid

Authors: Eleftherios I. Paschalis, James Chodosh, Ralph A. Sperling, Borja Salvador-Culla, Claes Dohlman

Affiliation: Massachusetts Eye and Ear Infirmary / Harvard Medical School, Boston, MA, USA.

Objective: To present a novel design of an implantable glaucoma valve based on ferrofluidic nanoparticles and to compare it with a well-established FDA approved valve.

Methods: A glaucoma valve was designed using soft lithography techniques utilizing a water-immiscible magnetic fluid (ferrofluid) as a pressure-sensitive barrier to aqueous flow. Two rare earth micro magnets were used to calibrate the opening and closing pressure. In-vitro flow measurements were performed to characterize the valve and to compare it to AhmedTM glaucoma valve. The reliability and predictability of the new valve was verified by pressure/flow measurements over a period of three months and X-ray diffraction (XRD) analysis over a period of eight weeks. In vivo assessment was performed in three rabbits.

Results: In the in vitro experiments, the opening and closing pressures of the valve were 10 and 7 mmHg, respectively. The measured flow/pressure response was linearly proportional and reproducible over a period of three months (1.8 ml/min at 12 mmHg; 4.3 ml/min at 16 mmHg; 7.6 ml/min at 21 mmHg). X-ray diffraction analysis did not show oxidization of the ferrofluid when exposed to water or air. Preliminary in vivo results suggest that the valve is biocompatible and can control the intraocular pressure in rabbits.

Conclusions: The proposed valve utilizes ferrofluid as a passive, tunable constriction element to provide highly predictable opening and closing pressures while maintaining ocular tone. The ferrofluid maintained its magnetic properties in the aqueous environment and provided linear flow to pressure response. Our in-vitro tests showed reliable and reproducible results over a study period of three months. Preliminary in-vivo results were promising, and an in depth investigation of the device's performance in rabbits is underway.

Study supported by: Boston Keratoprosthesis Fund

Conflict of interest: None

Corresponding author email address: ep@meei.harvard.edu



Title: The role of Tumor Necrosis Factor Alpha in Glaucoma after Boston Keratoprosthesis: Preliminary Data

Authors: Elise V. Taniguchi¹, Eleftherios I¹. Paschalis, Alja Crnej¹, Kathryn Colby¹, Louis Pasquale², James Chodosh¹, Claes H. Dohlman¹, Lucy Q. Shen².

Affiliations: Massachusetts Eye and Ear Infirmary, Department of Ophthalmology, ¹Cornea and ²Glaucoma Service, Harvard Medical School, Boston, MA, USA

Objective: Glaucoma is a long-term vision threat in patients with Boston Keratoprosthesis (B-KPro) implantation. Recent studies suggested that B-KPro patients are more likely to develop glaucoma and to suffer from a faster progression of the disease. Tumor necrosis factor alpha (TNF- α) is a pluripotent cytokine, which is up regulated during tissue ischemia and wound healing and can mediate retinal ganglion cell (RGC) layer apoptosis. The persistent corneal wound healing in B-KPro subjects can be a source of continuous secretion of TNF- α , which may explain the high prevalence of glaucoma in these patients. This study evaluated the levels of soluble TNF- α (sTNF- α), sTNFR-I and II receptors and leptin, a neurotrophic factor, in the blood of patients with and without BKPro (chronic angle closure glaucoma and narrow angle patients).

Methods: Twenty-seven patients, including 12 with B-KPro implantation (B-KPro) and 15 without B-KPro implantation (non B-KPro), were recruited to participate in this study. Humphrey visual field (HVF) test, disc photographs (DP) and venous blood draw were performed. Mean Deviation (MD) was accessed from HVF and cup disc (C/D) ratio was accessed from DP. Intraocular pressure (IOP) and body mass index (BMI) were also measured on the day of recruitment. Venous blood was collected in the morning hours using EDTA tubes from 7 B-KPro and 9 non B-KPro patients. sTNF- α , sTNFRs and leptin plasma levels were quantified with an enzyme-linked immunosorbent assay (ELISA) and for erythrocyte sedimentation rate (ESR) using the Westergren Method.

Results: Median \pm standard error of means for age (59 \pm 3.7 years), BMI (25 \pm 1.5), IOP (15 \pm 1 mmHg) and ESR (9 \pm 1.8mm/hr) were similar among the patients (n = 16) who had venous blood analyzed (p>0.07; Mann-Whitney test). Likewise, sTNF- α (1.4 \pm 0.2 ng/mL), sTNFR-I (911 \pm 55 ng/mL), sTNFR-II (2433 \pm 191 ng/mL) and leptin (18.463 \pm 5.679 pg/mL) levels were also not statistically different (p>0.11; M-W test) among the groups; however, the sTNF- α /sTNFR-I ratio was significantly higher in the BKPro group (0.0022) compared to the non B-KPro (0.0013; p=0.04; M-W test). Among patients who had clinical features analyzed (n = 27), eyes with B-KPro (n=14) had similar MD on HVF as eyes with chronic angle closure glaucoma (n=12), but significantly worse MD than eyes with narrow angles (n=18)(p<0.001)(Kruskal-Wallis). No difference was found in C/D ratio among eyes with and without B-KPro.

Conclusions: Preliminary results demonstrated elevated levels of sTNF- α to sTNFR-I in the blood of B-KPro patients. Persistent corneal wound healing can be a source of inflammation, increasing the levels of sTNF- α , which may be responsible to mediate retinal ganglion cell damage. Further evaluation of a larger sample size will help elucidate the role of sTNF- α in glaucoma after Boston Keratoprosthesis implantation.

Study supported by: Massachusetts Lions Eye Research Fund and Boston, Keratoprosthesis Research Fund.

Conflict of interest: None

Corresponding author email address: Elise_Taniguchi@meei.harvard.edu



KPro Study Group

9th KPro Meeting
April 12, 2014 Salzburg, Austria



P11

Title: Surface Epithelialization of the Type I Boston Keratoprosthesis Front Plate: Immunohistochemical and High-Definition Optical Coherence Tomography Characterization

Authors: Kimberly C. Sippel, Lee Kiang, Mark I. Rosenblatt, Rachel Sartaj, Ana G. Alzaga, Szilard Kiss, Nathan M. Radcliffe, Donald J. D'Amico

Affiliations: Weill Cornell Medical College/ New York-Presbyterian Medical Center, NY, NY, USA.

Objective: To characterize a transparent tissue layer partially covering the anterior surface of the type 1 Boston permanent keratoprosthesis front plate in six patients.

Methods: The tissue over the front plate was easily scrolled back as a single transparent layer using a sponge. In two cases, histopathologic analysis was undertaken. The relationship of the tissue to the keratoprosthesis device was further characterized using spectral domain high-definition optical coherence tomography (HD-OCT).

Results: The transparent tissue layer was identified in six of twelve consecutive patients who had undergone implantation of a type 1 keratoprosthesis with the "snap on" design available since 2007. Histopathologic analysis revealed the tissue to be non-keratinized squamous epithelium. The tissue was easily discerned by HD-OCT and was of substantial thickness near the external junction between the keratoprosthesis device and the carrier corneal tissue. In four cases, visual acuity was unaffected by the presence of this tissue. In two cases, a prominent tissue margin temporarily obscured the visual axis and reduced visual acuity; this resolved with mechanical central debridement and has not recurred.

Conclusions: The transparent tissue layer covering the anterior surface of the type I Boston keratoprosthesis front plate was found to represent non-keratinized squamous epithelium, most likely of corneal or conjunctival epithelial origin. This potentially represents a further step in bio-integration of the keratoprosthesis device. In particular, epithelial coverage of the critical junction between the device and the carrier corneal tissue might serve an important barrier function and further reduce the incidence of infection and extrusion of the type 1 Boston permanent keratoprosthesis.

Study supported by: Research for Preventing Blindness grant

Conflict of interest: None

Corresponding author email address: kcs2002@med.cornell.edu



KPro Study Group

9th KPro Meeting
April 12, 2014 Salzburg, Austria



P12

Title: Evaluation of a trephine adapter for preparation of corneal tissue during Boston Keratoprosthesis (KPro) Surgery

Authors: Joshua C. Teichman, Behrooz Azizi, Salina Teja, Ronan Conlon, Kashif Baig

Affiliation: University of Ottawa Eye Institute, Ottawa, Ontario, Canada

Objective: To assess centration accuracy and precision of an adapter used in trephination, developed for Boston Keratoprosthesis donor cornea tissue preparation.

Methods: Thirty corneoscleral rims were trephined. Ten donor corneas were prepared by trephining the 8mm cut followed by the 3mm cut (Group 1). Ten corneas were prepared by trephining the 3mm cut followed by the 8mm cut (Group 2). Ten corneas were prepared by using our adapter which allows for the cuts to be made almost simultaneously (Group 3). The centration of the two cuts was measured using computer software (Adobe Photoshop, San Jose, CA). Descriptive and inferential statistics were performed using Stata 13 (StataCorp LP, College Station, TX).

Results: The corneal grafts prepared in Group 1 had a mean distance between the centers of the two cuts of 0.388mm (SD 0.109). The grafts prepared in Group 2 had a mean decentration of 0.135mm (SD 0.056). The simultaneous method of trephination revealed a mean decentration of 0.185mm (SD 0.042). There was a statistically significant difference in centration between Group 1 and Group 2 ($p < 0.001$). There was a statistically significant difference in centration between Group 1 and Group 3 ($p < 0.001$). There was no statistically significant difference in centration of the grafts between Group 2 and Group 3 ($p=0.433$).

Conclusions: The newly designed device had the smallest standard deviation and hence was the most predictable (Group 3). The trephine adapter produced corneal grafts that were more centered than those prepared using the 8mm punch first (Group 1) but less centered than those prepared using the 3mm punch first (Group 2). This was a product of the adapter not being perfectly centered. Our study demonstrates that a device, which cuts the corneal tissue simultaneously, yields more predictable grafts for Boston Kpro surgery and with further improvement on centration, may be an ideal method to prepare the donor corneal rim for surgery.

Study supported by: University Medical Research Fund, University of Ottawa

Conflict of interest: None

Corresponding author email address: kbaig@toh.on.ca josh.teichman@gmail.com



- Title:** Oversized titanium back plate in Boston Keratoprosthesis: anatomical results
- Authors:** Andrea Cruzat, Alja Črnej, Elise Taniguchi, Claes H. Dohlman, Kathryn A. Colby.
- Affiliation:** Cornea Department, Massachusetts Eye & Ear Infirmary, Harvard Medical School, Boston, MA, USA.
- Objective:** To study the anatomy of the graft-host junction and angle after Boston keratoprosthesis (KPro) surgery with oversized and standard titanium backplates by anterior segment OCT (AS-OCT) as well as the incidence of retroprosthetic membranes.
- Methods:** 12 patients with oversized titanium Boston KPro backplates and 12 patients with standard backplates were imaged by AS-OCT 3 to 12 months after KPro surgery. The oversized backplates were 1mm larger in diameter than the trephined host. In the standard cases the backplate is the same size as the trephined host. The location of the graft-host junction in relation to the backplate, the corneal thickness in the graft-host junction, and the chamber angle were assessed. The clinical outcomes and incidence of retroprosthetic membrane formation in this cohort were also assessed by retrospective review.
- Results:** With the oversized backplate, the wound was completely clamped in all 4 quadrants, restricting swelling and associated with decreased wound thickness. In the standard backplate there was clamping of the graft but not the host in most cases resulting in a significantly thicker graft-host junction. Even though the angle was not always visible due to the titanium backplate, when visible, there was no significant difference in angle anatomy between the two groups. Over an average 18-month follow-up period (range 3 to 40 months) none of the patients in the oversized backplate group developed a significant retroprosthetic membrane.
- Conclusions:** Oversized KPro backplates effectively clamp the graft-host junction without adverse effects on angle anatomy or wound healing. This may be one strategy to provide better wound apposition, reduce retroprosthetic membrane formation, and reduce the likelihood of angle closure from iris synechiae to the wound.

Study supported by: Keratoprosthesis Research Fund

Conflict of interest: None

Corresponding author email address: andrea_cruzat@meei.harvard.edu



Title: A case of Ahmed glaucoma valve implantation for secondary glaucoma after modified osteo-odonto-keratoprosthesis (MOOKP)

Authors: Masahiko Fukuda¹, Etsuo Chihara², Sachiko Okuyama¹, Keizo Watanabe¹, Koji Sugioka¹, Suguru Hamada³, Christopher Liu⁴, Yoshikazu Shimomura¹

Affiliations: ¹Department of Ophthalmology, Kinki University Faculty of Medicine; ²Chihara Eye Clinic; ³Department of Oral Surgery, Kinki University Faculty of Medicine, Japan; ⁴Sussex Eye Hospital, Brighton, UK

Purpose: We report a case of Ahmed glaucoma valve implantation for secondary glaucoma after modified osteo-odonto-keratoprosthesis (MOOKP).

Case: The case was a 46 y.o. female. She had suffered from bilateral ocular surface chemical injury with sulfuric acid. Both ocular surface damages were very serious with diffuse corneoscleral melting and corneal perforation, which were treated with sclerocorneal graft with Gunderson conjunctival coverage surgery. At her first visit to us, both her ocular surfaces were covered by heavily scarred conjunctival tissues and visual acuities were light perception in both eyes. We performed MOOKP surgery (5/24/2010, stage 1 and 8/30/2010, stage 2) in her left eye. The surgery went well and her corrected visual acuity recovered to 1.5. However, 2 years and 5 months after surgery, she developed secondary glaucoma with an enlarged disc cupping and thinning of perifoveal retinal thickness. Therefore, we performed Ahmed glaucoma valve implantation at the supero-temporal meridian on 4/10/2013. The shunt tube was inserted into the anterior chamber without any low tension or choroidal detachment. On 4/13/2013, heavy vitreous hemorrhage was noted, but it resolved within two months and corrected visual acuity recovered to 0.7 with normal phosphene ocular pressure and slowdown of glaucomatous visual field deterioration in December 2013.

Conclusion: Tube shunt surgery is considered to be the only option for the treatment of secondary glaucoma after MOOKP. In our case, its efficacy was well confirmed.

Study supported by: N/A

Conflict of interest: None

Corresponding author email address: fukuda-m@med.kindai.ac.jp



KPro Study Group

9th KPro Meeting
April 12, 2014 Salzburg, Austria



P15

Title: Long-term outcomes of frozen and fresh corneal donor carriers for keratoprosthesis surgery

Authors: Marie-Claude Robert^{1,2}, Mona Harissi-Dagher¹

Affiliations: ¹ Centre Hospitalier de l'Université de Montréal (CHUM) – Notre Dame Hospital, 1560 Sherbrooke East, Montreal, QC, H2L 4M1, Canada
² Cornea fellow, Massachusetts Eye and Ear Infirmary, 243 Charles St, Boston MA 02114

Objective: We previously demonstrated the safety and efficacy of frozen corneal grafts as carriers for the Boston type 1 keratoprosthesis (KPro). In this study, we report the long term visual outcomes and complications associated with the use of both frozen and fresh corneal donor carriers.

Methods: This is a prospective study of 37 patients undergoing KPro surgery with either fresh or frozen corneas as carriers. Allocation of fresh versus frozen corneal grafts depended on availability from the Québec Eye Bank. Perioperative data has been previously reported. Data is reported up to 4 years of postoperative follow-up. Patients having received a fresh or a frozen donor carrier were compared regarding postoperative visual acuity (VA), device retention and postoperative complications.

Results: 19 patients received a fresh corneal graft carrier and 18 patients received a frozen corneal graft carrier during KPro surgery. Demographic characteristics as well as preoperative VA and ocular comorbidities were similar between both groups. At postoperative two years, median VA was 20/200 (range: 20/40 - HM) in the fresh cornea group and 20/200 (range: 20/40 - LP) in the frozen cornea group. At 3 and 4 years, eyes with a frozen carrier tended to have better VA. Inflammation and retroprosthetic membrane formation were the most common complications with similar rates between the two groups. Corneal melt occurred in 11% of fresh carriers and 22% of frozen carriers, with half developing after infectious keratitis. At 3 years, the device retention rate was 100%. One case of extrusion occurred in the frozen carrier group at postoperative 39 months.

Conclusions: Our data suggests that frozen and fresh corneal donors are equally safe as carriers for the Boston type 1 KPro. Inflammatory complications did not show an association with carrier graft type. Graft-related complications remained rare over long-term follow-up.

Study supported by: Fonds de Recherche en Ophtalmologie de l'Université de Montréal

Conflict of interest: None

Corresponding author email address: Marie-Claude_Robert@meei.harvard.edu



Title: A drug eluting contact lens

Authors: Joseph B. Ciolino^{1, 2, 3, *}, Amy E. Ross^{1, 2, 3,} Borja Salvador-Culla^{1, 2, 3,} Rekha Tulsan^{1,}
Daniel S. Kohane^{2, 3, *}

Affiliations:
¹ Department of Ophthalmology, Massachusetts Eye and Ear Infirmary, Boston, MA 02114, USA
² David H. Koch Institute for Integrative Cancer Research, 77 Massachusetts Ave, Building 76-66, Massachusetts Institute of Technology, Cambridge, MA 02139, USA
³ Laboratory for Biomaterials and Drug Delivery, Department of Anesthesiology, Division of Critical Care Medicine, Boston Children's Hospital, Harvard Medical School, Boston, MA 02115, USA

Objective: To report the development and performance of a drug-eluting contact lens.

Methods: Latanoprost-eluting contact lenses were created by encapsulating latanoprost poly(lactic-co-glycolic acid) films in methafilcon by ultraviolet light polymerization. Release kinetics were evaluated in vitro and in vivo.

Results: In vitro studies showed an early burst of drug release followed by sustained release for one month. The lenses appeared safe in cell culture and animal studies. In vivo, single contact lenses were able to achieve, for at least one month, latanoprost concentrations in the aqueous humor that were comparable to those achieved with topical latanoprost solution, the current first-line treatment for glaucoma.

Conclusions: This contact lens design can potentially be used as a treatment for glaucoma and as a platform for other ocular drug delivery applications.

Study supported by: This research was funded by NEI 1K08EY019686-01 (JBC), Massachusetts Lions Eye Research Fund (JBC), New England Cornea Transplant Fund (JBC), NIGMS GM073626 (DSK), Eleanor and Miles Shore Foundation (JBC), and by a Career Development Award from Research to Prevent Blindness, Inc., NY, NY (JBC).

Conflict of interest: JBC and DSK are listed on a published patent related to the drug-eluting contact lens.

Corresponding author email address: Joseph_Ciolino@meei.harvard.edu



COMPLICATIONS AND MANAGEMENT

Chair: K. Hille, J. Chodosh

28

Title: Endoscopic Cyclophotocoagulation in Refractory Glaucoma after Osteo-Odonto Keratoprosthesis in Stevens-Johnson Syndrome

Authors: Matteo Forlini, Cesare Forlini

Affiliation: Department of Ophthalmology, Hospital S. Maria delle Croci, Ravenna, Italy

Objective: To report successful treatment of refractive glaucoma in patient submitted to osteo-odonto-keratoprosthesis (OOKP) surgery for Stevens-Johnson syndrome (SJS).

Methods: An interventional case report

Results: The patient is a 62 year-old Indian man with known Stevens-Johnson syndrome (SJS) since 1972 secondary to tetracycline therapy, with bilateral dry eye and corneal blindness. He underwent symblepharon release surgery with mucous membrane graft in both eyes. OOKP surgery was later performed on the left eye. He was submitted to two Ahmed valve implants to control secondary glaucoma but visual fields continued to worsen; hence, he underwent endoscopic 140° cyclophotocoagulation with good control of IOP.

Conclusions: Endoscopic cyclophotocoagulation as alternative treatment provides good results in refractory glaucoma after OOKP surgery.

Study supported by: N/A

Conflict of interest: None

Corresponding author email address: matteoforlini@gmail.com



KPro Study Group

9th KPro Meeting
April 12, 2014 Salzburg, Austria



29

- Title:** Management of Corneal Melt Associated with Keratoprosthesis
- Authors:** Liqiang Wang, Yifei Huang
- Affiliation:** Chinese People Liberty Army general Hospital, Beijing 100853, China
- Objective:** To describe the surgical techniques to repair corneal melt on Boston Type 1 keratoprosthesis (KPro) and Micof KPro.
- Methods:** Technique description.
- Results:** After having affixed a corneal lamellar graft to cover the exposed area of the KPro, the KPro back plate is secured using 6-0 nylon sutures; the conjunctiva from the patient's fornix is loosened and used like a flap to recover the lamellar cornea. Buccal mucosa and auricular cartilage is used in cases of MICOF KPro corneal melting.
- Conclusions:** All techniques provide surgeons methods to repair KPro-related corneal melts.
- Study supported by:** N/A
- Conflict of interest:** None
- Corresponding author email address:** Liqiangw301@gmail.com



KPro Study Group

9th KPro Meeting
April 12, 2014 Salzburg, Austria



30

- Title:** Reusing a Boston KPro in the management of corneal melting: Report of three cases
- Authors:** Neuhann, Th, Neuhann, I
- Affiliation:** Ärztezentrum, Helene-Weber-Allee 19, 80637 München - Germany
- Objective:** Following sheer emergency-necessity, we have reused Boston KPros in 3 cases of acute corneal meltdown after Boston KPro Implantation.
- Results:** We report the situations, the technical aspects and experiences and the outcomes. No complications attributable to the reuse were encountered, despite unexpected situations that had to be taken care of.
- Conclusion:** Anxious clinging to approvals etc. may not be in the patients' best interest – responsible creative dealing with extreme situations in accordance with a thoroughly informed patient's decision is a surgeon's well understood duty.
- Study supported by:** N/A
- Conflict of interest:** None
- Corresponding author email address:** prof@neuhann.de



Title: Management of recurrent retroprosthetic membrane formation following Boston type 1 keratoprosthesis implantation

Authors: Canan Aslı Utine, Muhsin Altunsoy, Ferda Çiftçi

Affiliation: Yeditepe University, Department of Ophthalmology, Istanbul, Turkey.

Objective: Evaluation of recurrent retroprosthetic membrane (RPM) formation following Boston type 1 keratoprosthesis (KPro) implantation that requires multiple interventions.

Methods: A 31 year-old male patient who had had bilateral retinal detachment after an RPG (Rocket Propelled Grenade) explosion at the age of 15 and had undergone multiple pars plana vitrectomy, silicone oil injection, and penetrating keratoplasty surgeries was admitted to our hospital. At the time of admission, he was monocular with best corrected visual acuity of counting fingers from 1 meter in the better eye. This eye had aphakia, limbal stem cell deficiency, corneal conjunctivalization of 7 clock hours, deep and superficial stromal neovascularization, and history of immunological graft rejection. Aphakic type of Boston Type 1 Kpro implantation was performed in this eye.

Results: Postoperatively the visual acuity was 0.2 Snellen lines. Previously present macular scar formation, proliferative vitreoretinopathy and optic nerve atrophy limited further visual gain. Postoperative treatment of topical vancomycin bid, 4th generation fluoroquinolone bid and prednisolone acetate bid were continued throughout the follow-up of 36 months, where no complications were seen including loss of stabilization of the Kpro, melting at the carrier corneal tissue, epithelial defect or glaucoma. However, due to recurrent RPM formation, the patient underwent repeated Nd:YAG laser membranotomies (1.0-2.0 mJ) and subtenon triamcinolone injections at 5th, 14th and 25th months. Additionally, Nd:YAG laser membranotomy (1.0-2.0 mJ) and intravitreal triamcinolone and bevacizumab injections were performed at 30th month.

Conclusions: The most common complication after Boston type 1 Kpro implantation is RPM formation. In its early stages, it can be treated with Nd:YAG laser membranotomy, while thick and vascularized membranes necessitate surgical resection. Previous multiple intraocular surgeries present a risk factor for RPM formation. In eyes with recurrent RPM that need repeated interventions, long term topical, subtenon or intraocular anti-inflammatory treatment may be needed to prevent RPM formation.

Study supported by: N/A

Conflict of interest: None

Corresponding author email address: cananutine@gmail.com



- Title:** Sterile Vitritis after Boston Keratoprosthesis
- Authors:** Christina M. Grassi, Alja Crnej, Kathryn Colby, Claes Dohlman, James Chodosh.
- Affiliation:** Massachusetts Eye and Ear Infirmary, Boston, MA
- Objective:** To revisit the clinical paradigm of sterile vitritis in Boston keratoprosthesis (Kpro) recipients with delayed, culture-negative, vitreous inflammation.
- Methods:** A retrospective chart review was performed of 346 adult patients with a Boston Kpro, performed by three surgeons at the Massachusetts Eye and Ear Infirmary between January, 2000 and August, 2013. Patient demographics, treatments, and outcomes were recorded and analyzed.
- Results:** 38/346 Boston KPro recipients developed vitreous inflammation between 2 days and 8.5 yrs after surgery. 23/38 patients had no obvious cause for vitreous cells. 20/23 had Type I KPros. 6/23 had prior auto-immune disease. 10/23 had repeat episodes (32 total events, median 3, range 2-7). Mean time between repeat episodes was 8.66 months (range 2 wks-7.2 yrs) Prior to each episode, all patients were on a fluoroquinolone, 16/23 on prednisolone acetate, and 9/23 on vancomycin. On presentation, 17/23 received retrotenons injection of triamcinolone acetate (20-40 mg). 7/23 patients presented with signs and symptoms suggestive of infectious endophthalmitis. 11/23 had a vitreous tap for culture; all of these vitreous samples were negative except for 1 patient with *S. epidermidis*. Vision decline was variable (median loss of 6.5 lines on Snellen chart, range 0-24). Median time to best recovered vision was 13.5 weeks, but 5/23 never recovered baseline vision. 17/23 developed late complications, including retroprosthetic membrane (13), glaucoma (8), cystoid macular edema (3), and retinal detachment (2).
- Conclusions:** Many cases of vitreous inflammation after Boston KPro implantation have no identifiable trigger, and are termed "sterile vitritis". The paradigm for sterile vitritis after KPro includes sudden, painless loss of vision with full recovery of vision upon treatment with periocular steroids. However, this model may not apply in all cases. Not all patients with sterile vitritis after KPro recover baseline vision. Patients with a Boston KPro can present with vitritis that mimics infectious endophthalmitis, yet be culture negative. Full recovery of baseline visual acuity is not guaranteed. Roughly 45% of sterile vitritis cases recur, despite chronic topical corticosteroids. Repeat idiopathic vitreous inflammation may be particularly difficult to treat. Idiopathic vitritis may represent just one of several manifestations of chronic inflammation after Boston KPro.

Study supported by: N/A

Conflict of interest: None

Corresponding author email address: Christina_Grassi@meei.harvard.edu



KPro Study Group

9th KPro Meeting
April 12, 2014 Salzburg, Austria



33

Title: Retinal detachment prevention in KPro eyes

Authors: David Rooney¹; Robert Morris^{2,3,4}; John S. Parker²

Affiliations: ¹University of Alabama at Birmingham School of Medicine; ²Department of Ophthalmology, University of Alabama at Birmingham School of Medicine; ³Retina Specialists of Alabama; ⁴President, The Helen Keller Foundation for Research and Education, Birmingham, Alabama, USA.

Objective: Placement of a permanent keratoprosthesis (KPro) is an increasingly commonplace treatment for severe corneal opacification. However, KPro eyes are at high lifetime risk of rhegmatogenous retinal detachment (RRD), proliferative vitreoretinopathy (PVR), and tractional retinal detachment (TRD). Despite the restoration of a clear visual axis, visualization and treatment of peripheral retinal defects in KPro eyes remains problematic. We propose a method of retinal detachment (RD) prophylaxis for selected K-Pro eyes that can be performed concurrently with KPro placement.

Methods: After trephination for KPro placement, a temporary keratoprosthesis (TKP) is sutured in place. Pars plana vitrectomy is then performed to prevent formation of vitreous membranes secondary to chronic inflammatory conditions, and to eliminate traction from the vitreous mass. Encircling laser prophylaxis is performed on the entire peripheral retina, so as to produce a “second ora” (ora secunda cerclage, OSC) posterior to the retinal region at greatest risk of causative retinal tears. The TKP is removed and the KPro is then emplaced.

Results: A 42-year-old white male with congenital glaucoma and subsequent bilateral corneal opacification, had lost the right eye to RRD/PVR/TRD six months after KPro emplacement. Six months later, the left eye received the above treatment. Eighteen months postoperatively, the left eye remains free of complications, seeing 20/100 at distance and 20/25 near equivalent with a low-vision aid. The retina remains stable with a clear vitreous cavity and KPro clear visual axis.

Conclusions: Consecutive TKP/VIT/OSC/K-Pro in a single procedure provides effective and permanent prophylaxis for retinal detachment. Any KPro eye with high lifetime risk for retinal detachment, or any monocular patient, should be considered for the combined procedure.

Study supported by: N/A

Conflict of interest: None

Corresponding author email address: dmr123@uab.edu (David Rooney)



- Title:** Management of retinal detachment in osteo-odonto keratoprosthesis (OOKP).
Case report
- Authors:** Cesare Forlini, Adriana Bratu, Matteo Forlini, Paolo Rossini, MD
- Affiliation:** Department of Ophthalmology, Hospital S. Maria delle Croci, Ravenna, Italy
- Objective:** To report successful treatment of RD in osteo-odonto keratoprosthesis
- Methods:** An interventional case report
- Results:** The patient came to our observation with a visual acuity of uncertain light perception due to a thick cyclitic membrane which didn't allow fundus visualization. The OOKP consists in a single rooted tooth with its surrounding alveolar bone used as a carrier for a PMMA optical cylinder therefore not even an echography could give us further information on the retina. As a first approach we decided to remove the membrane with a mini-invasive 25 gauge vitrectomy system but we soon realized that this method was ineffective, so we enlarged a sclerotomy and checked the eye from the inside with an endoscopic probe. At this point we found out that there was a total rhegmatogenous-tractional retinal detachment with PVR, so we changed strategy and preceded removing the OOKP and performing a 20 gauge vitrectomy. We opened the anterior scleral surface using a 7.25 mm Franceschetti trephine and, after checking the infusion with the endoscopic probe, the thick cyclitic membrane is totally removed with scissors and PFCL is injected "open-sky" in the vitreous chamber. After positioning a Landers temporary keratoprosthesis, a 20 gauge vitrectomy is performed using a wide-angle viewing system (BIOM). Epiretinal membranes are removed bimanually, using an endoillumination probe with pic. IGC-assisted ILM peeling is also performed. After a 360° DG* endolaser photocoagulation, 1000 cs silicone oil is used to tamponade the retina and the OOKP
- Conclusions:** Patient visual outcome was 1/10 at 2 year follow-up.
- Study supported by:** N/A
- Conflict of interest:** None
- Corresponding author email address:** forlinic@forlinic.it



- Title:** Retinal Detachments in Eyes after Boston Keratoprosthesis Type 1
- Authors:** Sachin Jain, Clement C. Chow, Jennifer I. Lim, Lawrence J. Ulanski, Jose De la Cruz, Maria S. Cortina, Felix Y. Chau
- Affiliation:** University of Illinois at Chicago, Illinois Eye and Ear Infirmary, Chicago, IL, USA
- Objective:** To report the frequency, timing, visual significance, contributing factors, and management of retinal detachment (RD) after successful Boston Keratoprosthesis Type I (KPro) implantation.
- Methods:** A retrospective chart review was conducted of consecutive KPro implantations at a single institution over a 5-year period. Preoperative and postoperative best-corrected visual acuity (BCVA), ocular co-morbidities, anatomic outcomes, surgical interventions, and complications were analyzed.
- Results:** One hundred and three KPros were implanted into 95 eyes of 94 patients over a 5-year period. Fourteen of the 95 eyes (14.7%) developed RDs during a median follow-up of 27.5 months (range 12-58). Pre-KPro diagnoses included HSV keratitis, chemical burn, aniridia, Peters anomaly, Fuchs' dystrophy, congenital glaucoma, end-stage glaucoma and limbal stem cell deficiency. Ten of 14 eyes had concomitant surgery, including intraocular lens removal (6), pars plana vitrectomy (PPVx, 5), silicone oil fill (2 for hypotony), Ahmed tube placement (2), pupilloplasty (1) and tarsorrhaphy(1). The median time from KPro placement to occurrence of RD was 9 months (range 0.5-40 months). Thirteen of 14 (92.9%) eyes underwent PPVx; only 3 eyes required KPro removal during RD repair. BCVA prior to KPro surgery was 1.91 ± 0.28 (logarithm of minimum angle of resolution \pm standard deviation). BCVA improved after KPro to 1.23 ± 0.58 ($p < 0.001$), but decreased after RD to 2.08 ± 0.31 . Ten of 13 eyes (77%) undergoing PPVx for RD achieved initial reattachment. Best BCVA post-repair was 2.02 ± 0.75 overall ($p = 0.77$), and 1.81 ± 0.69 for eyes with successfully attached retinas. ($p = 0.45$) However, 7 of these 10 eyes (70%) developed recurrent RDs and required a median of 2 PPVxs. Complications after KPro identified as contributing to RD included proliferative vitreoretinopathy (7), retroprosthetic membranes (7), hypotony (4), epithelial downgrowth (3), endophthalmitis (3), and choroidal detachment (3). BCVA at final follow-up was 2.19 ± 0.80 ; 2 of the 14 eyes achieved VA $> 20/400$ at final follow up.
- Conclusions:** RD is a significant complication after KPro surgery occurring in 14.7% of 95 eyes. The visual acuity gain after KPro surgery is lost when a retinal detachment occurs, despite good anatomic outcomes in a majority of eyes (77%) after RD repair. Various ocular coexisting co-morbidities and post-KPro complications contributed to RDs and decreased visual acuity.

Study supported by: Research To Prevent Blindness (RPB)

Conflict of interest: None.

Corresponding author email address: FelixYChauMD@gmail.com



Title: Treatment Outcomes of Cystoid Macular Edema in Patients with Boston Type I KPro

Authors: Randee C. Miller, Kaitlyn M. Wallace, Joshua H. Hou, Clement C. Chow, Jose De la Cruz, Maria S. Cortina, Felix Y. Chau

Affiliation: University of Illinois at Chicago, Illinois Eye and Ear Infirmary, Chicago, IL

Objective: Cystoid macular edema (CME) is a common complication of Boston Keratoprosthesis Type 1 (Kpro) implantation, for which there is no standard treatment protocol. In this study we report our experience with several established therapies for CME.

Methods: Medical records of all patients who underwent implantation of Kpro at the University of Illinois at Chicago, Illinois Eye and Ear Infirmary from Feb 2007- Nov 2012 were retrospectively reviewed. Eyes with CME as confirmed on spectral domain optical coherence tomography (SD-OCT) in the postoperative period were included. Outcome measures included: visual acuity (VA); intraocular pressure; SD-OCT macular thickness; type, frequency, and duration of treatment including topical steroids and non-steroidals, posterior sub-tenon (PST) and intravitreal triamcinolone (IVT), intravitreal bevacizumab, and dexamethasone implant (Ozurdex). Structural outcomes were categorized into resolution (R), improvement (I), stable (S), or worsened (W).

Results: 105 Kpro were implanted into 91 eyes of 85 patients over a 5-year period. 19 of 91 eyes (21%) were diagnosed with CME postoperatively. The median time from Kpro to diagnosis of CME was 3 months. The median follow up time was 21.9 months. The median VA at time of CME diagnosis was 20/200 and the median initial OCT macular thickness was 519 μm . 10 eyes had topical treatment only (3R, 3I, 2S, 2W). 9 eyes had additional treatments with injections: 1 had intravitreal bevacizumab (S); 1 had PST and IVT (S); 1 had PST, IVT and bevacizumab (W); 3 had at least one Ozurdex (1R, 2I) and 3 had PST, IVT, and Ozurdex (3I). The 8 steroid injected eyes received a median of 3 treatments over a median of 24.7 months. Overall, the median final VA was 20/250 ($p= 0.25$) and median final OCT macular thickness was 413 μm ($p= 0.005$). 4 eyes with pre-existing glaucoma had a transient pressure spike >30 mmHg following steroid injection; 3 were treated successfully with topical medication (3/4) and one required a glaucoma shunt procedure (1/4). There were no other ocular complications.

Conclusions: Treatment of CME following Kpro can be challenging. Corticosteroids remain a mainstay of treatment and anatomic improvement may occur in the absence of visual acuity improvement. Twelve of 19 eyes exhibited resolution or improvement of CME, including all 6 eyes treated with Ozurdex; four of these 12 eyes had improved visual acuity. Ozurdex may be beneficial in treating chronic Kpro CME.

Study supported by: Research To Prevent Blindness (RPB)

Conflict of interest: None.

Corresponding author email address: FelixYChauMD@gmail.com



BOSTON KERATOPROSTHESIS (PART 2)

Chair: J. Aquavella, G. Grabner

37

Title: Donor Corneal Transplantation versus Boston Type I Keratoprosthesis in Patients with Previous Graft Failures: A Retrospective Single Center Study

Authors: Esen K. Akpek; Sandra D. Cassard; Karen Dunlap; Sarah Hahn; Pradeep Y. Ramulu

Affiliation: The Wilmer Eye Institute, Johns Hopkins School of Medicine, Baltimore, MD, USA

Objective: To compare the short term visual outcomes and post-operative complications of donor penetrating keratoplasty (PK) and Boston type I keratoprosthesis (KPro) in patients who have previously failed one or more full thickness donor corneal transplants.

Methods: All patients age 18 and older with one or more prior PKs who underwent either a repeat PK or KPro procedure at The Wilmer Eye Institute, between January 2008 and December 2010 were considered. Patients with significant autoimmune/inflammatory ocular surface diseases and patients with postoperative follow-up of less than three months at the time of data collection were excluded. Data were collected regarding patient demographics, pre-operative characteristics, indication for the initial corneal transplantation, co-morbidities, concomitant procedures and post-operative complications. Only one surgical procedure in one eye was included for each patient. All KPro surgeries were retained in the analyses. Post-operative visual acuity and complication rates in each group were assessed.

Results: Fifty three patients underwent a repeat PK and 27 received a KPro implantation. Mean postoperative follow-up time was 19.5 months in the repeat PK group and 16.5 months in the KPro group. Eyes undergoing KPro had significantly worse mean pre-operative vision compared to repeat PK eyes (hand motions versus count fingers, $p = .01$), and more ocular co-morbidities. In the post-operative period a third (35%) of the patients in the PK group and 45% in KPro group achieved a best ever vision of 20/70. About half of the patients in each group (47% in PK group and 40% in KPro group) were able to retain this vision. Two year rate of failure to retain a visual acuity better than the baseline value was higher for PK eyes, though not at a statistically significant ($HR = 1.67$, 95% $CI = 0.78-3.60$, $p = .19$). Two year cumulative rate of graft failure (loss of clarity for PK group and removal/replacement for KPro group) was higher for PK eyes ($HR = 3.23$, 95% $CI = 1.12-9.28$, $p = 0.03$). Post-operative complication rates for retinal detachment, endophthalmitis and glaucoma were same in both groups ($p = .6$ for all).

Conclusions: This retrospective, short-term case series demonstrates less frequent graft failure, greater visual improvement and greater likelihood of maintaining the visual improvement in KPro eyes compared to repeat donor PK. Larger, randomized studies are needed to further determine which patients are most likely to succeed with repeat PK and which would have better outcomes with a KPro surgery.

Study supported by: N/A

Conflict of interest: None

Corresponding author email address: esakpek@jhmi.edu



KPro Study Group

9th KPro Meeting
April 12, 2014 Salzburg, Austria



38

Title: Modification of Boston KPro type I surgery for cases with previous KPro extrusion

Authors: Jaime Etxebarria¹, José Abelairas², Ana Orive¹, Telmo Xabier Lerchundi¹, Esther Lozano¹, Beatriz Parente¹, Alaitz Santamaria¹, Raquel Feijoo¹, Nerea Martinez¹

Affiliations: ¹Hospital de Cruces, Bilbao, Spain; ²Hospital La Paz, Madrid, Spain.

Objective: To show a modification in Boston KPro type I by using a synthetic duramater layer in order to “transform” it into a Boston KPro type II.

Methods: This surgery has been already performed in three cases in which a previous extrusion of Boston Kpro I occurred. Previous photos, video surgeries and postop photos will be showed.

Results: Longest follow up is 3 years and shortest follow up 6 months. All the KPros remain stable up to date. We show the case of an eight years old boy with unique eye and previous 35 oculoplastic and eye surgeries due to a congenital disease in which we first performed Boston KPro I surgery. KPro finally extruded, and PKP should be performed until the eye got quiet. Four months later, KPro I modified surgery was performed, VA is slowly improving, he is self-sufficient, he has been schooled back again and eye remains quiet.

Conclusions: Boston KPro type I has not been approved by European Health Authorities yet. Boston KPro type II is an impossible device to achieve in Europe, so OOKP is an alternative for cases in which Boston KPro type I does not work. OOKP is a very difficult surgery to perform with different steps that are not easily accepted by the patients. We present a reasonable alternative for Boston KPro type II by using a modified Boston KPro type I.

Study supported by: N/A

Conflict of interest: None

Corresponding author email address: jaime.echevarriaecenarro@osakidetza.net



Title: Wound anatomy following Boston keratoprosthesis (KPro): Effects on RPM formation and development of glaucoma

Author: Kathryn Colby

Affiliation: Massachusetts Eye and Ear Infirmary, Boston Children's Hospital, Harvard Medical School, Boston, MA, USA

Objective: RPM formation is the most common complication after KPro, while glaucoma is the complication most likely to cause vision loss. Both can be challenging to manage. Wound anatomy, specifically discontinuities at the posterior graft-host junction, contributes to RPM formation and may also play a role in the development or progression of glaucoma after Boston KPro placement.

Methods: Clinical outcomes of patients with oversized titanium backplates were determined by review of medical records. Anatomy of the graft-host junction and angle of these patients were evaluated by anterior segment OCT.

Results: Twenty patients had oversized backplates placed from 2010-2014. In 14 patients, the backplate was 1.5 mm larger than the opening in the host cornea, while 5 were oversized by 1.0 mm and 1 by 0.75 mm. OCT imaging demonstrated that the oversized backplates provided complete support for the graft-host junction without inducing compromise of the angle. Two patients, both aniridics, developed RPM requiring laser treatment. One patient, an aniridic, developed high intraocular pressure requiring medical treatment, while one graft failure patient required glaucoma surgery during the follow-up period.

Conclusions: Wound anatomy plays a role in common and vision-threatening complications after Boston KPro. Complete apposition of the graft-host junction using an oversized KPro backplate appears to reduce RPM formation and development or progression of glaucoma.

Study supported by: N/A

Conflict of interest: None

Corresponding author email address: kacolby@meei.harvard.edu



Title: Boston Keratoprosthesis multicenter study: retention and vision.

Authors: Christopher J. Rudnisky,¹ Michael W. Belin,² Joseph B. Ciolino,³
for the Boston Type 1 Keratoprosthesis Study Group

Affiliations: ¹ Department of Ophthalmology, University of Alberta, Edmonton, Alberta, Canada
² University of Arizona Dept. of Ophthalmology & Vision Science, Tucson, Arizona
³ Department of Ophthalmology, Massachusetts Eye and Ear Infirmary, Harvard Medical School, Boston, MA

Objective: To report the retention and visual outcomes of the Boston Keratoprosthesis Type 1.

Methods: Forms reporting preoperative, intraoperative, and postoperative parameters were prospectively collected and subsequently analyzed at a central data collection site.

Results: A total of 300 eyes of 300 patients who underwent implantation of the Boston keratoprosthesis type device between January 2003 and July 2008 by 19 surgeons at 18 medical centers. 33.3% of eyes (n=100) had hand motions acuity and 14.3% (n=43) had only light perception. After an average of 17.1 ±14.8 months, visual acuity improved significantly (p<0.0001) to a mean final value of 0.89 ± 0.64 (20/150). There were also fewer eyes with hand motions acuity (8.5%; n=24; p=0.263) and significantly fewer with light perception (6.7%; n=19; p<0.0001), although 3.1% (n=9) progressed to no light perception. Multivariate analysis demonstrated three independent predictors of final visual outcome: chemical injury was associated with better final vision (p=0.0012), whereas aniridia (p=0.03) and AMD (p<0.0001) were associated with poorer vision. During the study period, 21 (7%) eyes failed to retain the device; the reasons for keratoprosthesis loss include sterile keratolysis (9), fungal infections (8), dense retroprosthetic membranes (3), and bacterial endophthalmitis (1). Multivariate analysis demonstrated 3 independent risk factors for keratoprosthesis loss: autoimmune disease, ocular surface exposure requiring a concomitant tarsorrhaphy, and number of prior failed penetrating keratoplasties.

Conclusions: The Boston keratoprosthesis type 1 seems to be a viable option for eyes that are not candidates for penetrating keratoplasty (PK).

Study supported by: This research was funded by NEI 1K08EY019686-01 (JBC), New England Cornea Transplant Research Fund (JBC) and by a Career Development Award from Research to Prevent Blindness, Inc., NY, NY (JBC).

Conflict of interest: None

Corresponding author email address: Joseph_Ciolino@meei.harvard.edu



KPro Study Group

9th KPro Meeting
April 12, 2014 Salzburg, Austria



41

- Title:** Globalization of keratoprosthesis surgery
- Author:** James Chodosh
- Affiliation:** Massachusetts Eye and Ear Infirmary, Harvard Medical School, Boston, MA, USA
- Objective:** To address the current status of keratoprosthesis globalization, world-wide, with special attention to use in less economically developed countries.
- Methods:** Review of the existing literature and discussion of obstacles and opportunities encountered in implementation of keratoprosthesis surgery in blind, indigent patients, world-wide.
- Results:** Implantation of keratoprostheses, including the modified osteo-odonto keratoprosthesis and the Boston keratoprosthesis, is increasing internationally, and in particular, in less economically developed nations with large proportions of indigent, corneal blind patients. Based on the published literature, specific complications, such as device extrusion and infectious endophthalmitis, may be more common in these settings.
- Conclusions:** Keratoprosthesis use in less economically developed countries is increasing. We can expect increased reports of severe complications after keratoprosthesis implantation, particularly in the poorest patients. New designs and approaches are needed before keratoprosthesis implantation can be fully globalized.
- Study supported by:** Research to Prevent Blindness, NY, NY
- Conflict of interest:** The author is an employee of the Massachusetts Eye and Ear Infirmary, where the Boston keratoprosthesis is manufactured.
- Corresponding author email address:** james_chodosh@meei.harvard.edu



- Title:** **Keratoprosthesis in the Filatov Institute: elaboration, study and results of application**
- Author:** Stanislav Iakymenko, Petro Kostenko
- Affiliation:** State Institution "The Filatov Institute of Eye Diseases and Tissue Therapy of the National Academy of Medical Sciences of Ukraine"
- Objective:** We perform keratoprosthesis to restore vision in patients with severe leucomas, unsuitable for optical corneal grafting. The problem of keratoprosthesis is being worked out in the Filatov Institute since 1966. The aim of the study was to analyse results of our methods of keratoprosthesis.
- Methods:** We have developed new constructions of keratoprostheses, new methods of operations as well as different ways of leucoma strengthening during this period. Complications associated with keratoprosthesis were studied; methods of their prevention and treatment were worked out. Keratoprosthesis according to the developed techniques has been performed in 1060 eyes of 1040 patients with severe leucomas of different aetiology: burns, 725 eyes (68.4%); trauma, 120 eyes (11.3%); keratitis and ocular pemphigoid, 108 eyes (10.2%); and bullous keratopathy, 107 eyes (10.1%). Visual acuity before keratoprosthesis consisted of light perception in 962 eyes (92%), and 98 eyes (8%) had minimal visual acuity (1/200–1/50). Both eyes were blind (visual acuity less than 1/200) in 955 patients (91.8%). Age of patients varied from 10 to 80 years. Period of blindness varied from 1 to 52 years.
- Results:** As a result of keratoprosthesis, visual acuity of $\geq 1/200$ was restored in 1023 of 1060 eyes (96.5%). Visual acuity of 20/200–20/20 was achieved in 716 eyes (67.5%). At the last follow-up visit visual acuity of $\geq 1/200$ was preserved in 806 eyes (76%), visual acuity of 20/200–20/20 was measured in 583 of 1060 eyes (55%) and good keratoprosthesis fixation in the cornea was achieved in 986 of 1060 eyes (93%). The minimal follow-up was 12 months (range, 12 months to 37 years, median 5 years). The best results were obtained using our "universal separable" construction of keratoprostheses (1978), "two-stage method" of the operation (1974) with application of combined methods of superficial and intralamellar leucoma strengthening using patient's oral mucosa and ear cartilage in vascularised leucomas or intralamellar corneal graft (posterior stroma and Descemet's membrane) in non-vascularised leucomas.
- Conclusions:** Our technique of keratoprosthesis is an effective method to restore vision in patients with leucomas unsuitable for optical corneal grafting. This is our solution of keratoprosthesis problem at present.
- Study supported by: N/A
- Conflict of interest: None
- Corresponding author email address: piter1812@gmail.com



- Title:** Our metods of surgical treatment of postburn glaucoma in patients before or after keratoprosthesis
- Author:** Stanislav Iakymenko, Petro Kostenko
- Affiliation:** State Institution "The Filatov Institute of Eye Diseases and Tissue Therapy of the National Academy of Medical Sciences of Ukraine"
- Objective:** Secondary glaucoma according to literature data is developed in 15-46,1% of cases in patients after severe consequences of eyeburns, in 8-57,4% it became the reason of functional loss of eye. Traditional antiglaucoma fistulizing operations in patients with postburn glaucoma (PG) are as a rule impossible or ineffective. In cases of corneal blindness in patients with PG conventional treatment is ineffective or is likely to have a poor prognosis. Keratoprosthesis (KP) surgery is often the procedure of choose in these cases. To investigate the long-term effects of our antiglaucoma operations – autoscleral cyclogoniodrainage with the strip of autosclera (ACGD(S)) and its modifications - cyclogoniodrainage with the fold of autosclera (ACGD(F)) and ACGD(F) with the simultaneous implantation of the Ahmed glaucoma valve (ACGD(A)) (implantation is conducted in our method) in patients with refractory postburn glaucoma.
- Methods:** This retrospective study analyzes 137 antiglaucoma operations performed in 128 eyes between 1996 and 2013. ACGD(S) was performed in 30 eyes (32 operations), ACGD(F) in 67 eyes (74 operations) and ACGD(A) in 31 eyes (31 operations). All patients with refractory postburn glaucoma had the scary changes in the anterior segment of eye after a burn. Before the operation intraocular pressure (IOP) level was increased in all patients – range 31-54 mmHg. Visual acuity in all patients equaled to light perception. KP was performed in 27 eyes, and in 101 eyes it was planned to perform. Definition of operation success was the compensation of IOP postoperative and in the follow-ups.
- Results:** Compensation of IOP occurred in all patients following ACGD(S), ACGD(F) and ACGD(A) in early postoperative period (less then 3 months). The compensation of IOP in the follow-up period (up to 5 years) occurred in 59.4% of cases after ACGD(S), in 78.4% of cases after ACGD(F), and in 83.9% of cases after ACGD(A). The IOP was reduced because new ways of aqueous humor outflow from the anterior chamber to the suprachoroidal space was created and the aqueous humor production was suppressed. In all patients with compensated IOP the light-perception was preserved and painful symptom was removed.
- Conclusions:** Use of ACGD(S), ACGD(F) and ACGD(A) allowed normalizing intraocular pressure and preserving visual functions in the majority of patients with refractory postburn glaucoma. However, we recommend ACGD(F) and ACGD(A) for these patients, because there is high risk of re-elevation of IOP after ACGD(S) within five years.
- Study supported by: N/A
- Conflict of interest: None
- Corresponding author email address: piter1812@gmail.com



42

KEYNOTE LECTURE: REMAINING OBSTACLES FOR ARTIFICIAL CORNEAS ?

- Author: Claes H. Dohlman
- Affiliation: Harvard Medical School/Massachusetts Eye and Ear Infirmary, Boston, MA, USA
- Designs: Almost all possible designs have been tried since 1950.
- Materials: Titanium very inert – gaining favor for non-transparent parts.
- Infections: Now, way down because of prophylactic antibiotics – about 0.1% per year.
Control mostly a matter of compliance with prophylaxis.
- Sterile vitritis: New insights.
- Tissue melt Device retention now good but still problems with inflammatory mediators and reduced resistance to enzymes – in autoimmune diseases, etc.
- Glaucoma: With infections and tissue melt reasonably under control glaucoma is now the main obstacle to long-term safety.
- Chronic inflammation: Hard to diagnose, follow. Can be a severe problem, dependent on preoperative history (trauma, uveitis, autoimmune diseases, etc.).
Retinal detachment has poor prognosis.
- Retroprosthetic membrane: Almost gone except in heavy inflammation.
- Cost: Decreasing. Inexpensive devices developed for the developing world. Cost-benefit ratios now reasonable.
- Epidemiology: Unmet need: how many people per year, worldwide, would need an artificial cornea, if procedure long-term safe?
- Summary outcomes: Infections and tissue melt reduced by a log unit over past two decades.
Retroprosthesis membrane almost eliminated. **But glaucoma ?**
- Corresponding author email address: claes_dohlman@meei.harvard.edu



PRECISION
that changes everything

Precision Laser Cataract Surgery

The **CATALYS** Precision Laser System combines a <600 femtosecond laser, gentle **Liquid Optics** Interface, and integrated 3D Full Volume Optical Coherence Tomography (OCT) **Integral Guidance** System to create precise incisions in the lens and cornea. The **CATALYS** Femtosecond Laser was developed in close collaboration with a medical advisory board of cataract experts from around the world.

The **CATALYS** Precision Laser System is approved for all incisions:

Capsulotomy • Lens Fragmentation • Corneal Arcuate Incisions • Corneal Primary Incisions and Sideports



Designed for Laser Cataract Surgery

The **CATALYS** System is the only laser platform designed from the beginning specifically for laser cataract surgery. It offers:

- Precise capsulotomies within 30µm
- Complete segmentation and softening of the cataract with adjustable grid sizing
- Multiple corneal incision centration options that are based on anatomical landmarks
- **Integral Guidance** System - proprietary 3D Full Volume Optical Coherence Tomography (OCT) and automated surface mapping algorithms that guide laser delivery
- **Liquid Optics** Interface, gentle docking with minimal intraocular pressure rise and clear optics for excellent imaging and laser delivery

Clinical images: First from left is owned by Abbott Laboratories. Images 2, 3 and 4 are courtesy of Jason Jones, MD - Jones Eye Clinic, Sioux City, Iowa.



CATALYS®
Precision Laser System

 **Abbott**
A Promise for Life



Introducing the new TECNIS® Multifocal Family of IOLs: A full range of vision, whatever life's focus.



TECNIS® Multifocal Family of IOLs

Provide patients with an **exceptional full range of vision** with enhanced performance at distances tailored to each individual patient lifestyle.

© 2013 Abbott Medical Optics, Inc.
www.AbbottMedicalOptics.com

TECNIS is a trademark owned by or licensed to Abbott Laboratories, its subsidiaries or affiliates.

2013.10.24-C17737

 **Abbott**
A Promise for Life